Clinics in Surgery

Research Article
Published: 15 Dec, 2021

Distal Strain Gauge Plethysmography with Selective Superficial Occlusion in Patients with Lower Limb Venous Incompetence and/or Obstruction – A Pilot Study

Johan Skoog[1], Oskar Nelzén[2], Margareta Ahle[3] and Helene Zachrisson[1]*

[1]*Department of Clinical Physiology and Department of Health, Medicine and Caring Sciences, Linköping University, Sweden*

[2]*Department of Thoracic and Vascular Surgery and Department of Health, Medicine and Caring Sciences, Linköping University, Sweden*

[3]*Department of Radiology and Department of Health, Medicine and Caring Sciences, Linköping University, Sweden*

Abstract

Background: Quantitative evaluation of venous function is important. The aim of this study was to assess if distal Strain Gauge Plethysmography (SGP) with superficial occlusion is able to quantify the hemodynamic importance of the superficial reflux component in patients with chronic venous disease.

Design and Methods: Twelve patients (fourteen limbs) with chronic venous disease were examined with Duplex Ultrasound (DUS), SGP and radiological imaging. SGP was also performed in eleven controls. SGP was used to measure refilling times (T_{50} and T_{90}, sec). A change in T_{50} >5 sec between SGP with and without occlusion of superficial veins was used to indicate a significant improvement.

Results: No significant improvements in T_{50} were seen in controls after superficial occlusion, and the median (min-max) change was -2 (-5–4) sec. DUS evaluation in patients displayed five limbs with superficial venous incompetence, one with deep incompetence, three with mixed incompetence, and five with no venous incompetence. Patients with superficial incompetence demonstrated greater improvements in T_{50} after superficial occlusion compared to controls (p=0.003). In patients with deep and mixed incompetence, no significant improvements in refilling times were seen after superficial occlusion (T_{50}, median (min-max), 3 (1-3) sec). In patients with no detected incompetence, no consistent improvement in T_{50} and T_{90} were identified after occlusion, and imaging revealed venous obstruction in four limbs and varicose pelvic/ovarian veins in one limb.

Conclusion: Distal SGP with superficial occlusion seems to have the potential to quantify the superficial component of reflux in relation to deep venous reflux or venous obstruction.

Keywords: Venous incompetence; Venous obstruction; Strain-gauge plethysmography Duplex ultrasound; Chronic venous disease

OPEN ACCESS

Correspondence:
Johan Skoog, Department of Clinical Physiology and Department of Health, Medicine and Caring Sciences, Linköping University, 58185 Linköping, Sweden,
E-mail: johan.skoog@liu.se

Received Date: *09 Nov 2021*
Accepted Date*: 08 Dec 2021*
Published Date*: 15 Dec 2021*

Citation:
Skoog J, Nelzén O, Ahle M, Zachrisson H. Distal Strain Gauge Plethysmography with Selective Superficial Occlusion in Patients with Lower Limb Venous Incompetence and/or Obstruction – A Pilot Study. Clin Surg. 2021; 6: 3388.

Background

Chronic venous disease is the result of venous reflux, venous obstruction or a combination of the two. Venous reflux may involve superficial veins, deep veins, or both. Duplex Ultrasound (DUS) is gold standard in the diagnosis of chronic venous disease and provide information on the anatomical distribution of the disease [1]. However, DUS does not permit an overall quantification of venous function. In the presence of combined deep and superficial reflux, it is difficult to evaluate the hemodynamic impact of the superficial versus the deep component on the total venous function, which could be of importance when assessing the probability of successful outcome after superficial treatment. Further, in case of suprainguinal venous obstruction DUS is less accurate [1-3]. And additional radiological imaging or intravascular ultrasound require contrast and sometimes ionizing radiation or are invasive. A recent study showed that approximately 15% of patients treated with venous stenting due to outflow obstruction had an earlier history of endovenous ablation of superficial veins with remaining symptoms after intervention [4]. This is probably explained by the fact that venous obstruction is more difficult to diagnose through non-invasive means. Thus, in selected patients it seems useful to have some additional non-invasive diagnostic tool to help evaluate the probability of venous obstruction as well as the hemodynamic

impact of superficial contra the deep reflux. We have developed a new method of Strain-Gauge Plethysmography (SGP) with standardized selective superficial occlusion for evaluation of refilling time, i.e., the time in seconds to reach steady-state venous volume after activation of the calf muscle pump and the foot pump [5]. The purpose was to separate the components of superficial and deep venous reflux from each other. By using our technique, we have shown that refilling times are comparable between preoperative examinations with superficial occlusion and postoperative examinations without superficial occlusion in patients with great saphenous vein incompetence, i.e., it seems possible to predict the hemodynamic outcome after intervention [5]. During the use of SGP in clinical practice, we have noted that some patients do not improve their refilling time after superficial occlusion. This could be due to essentially four conditions; i) no venous reflux; ii) isolated deep venous reflux; iii) mixed venous reflux with more pronounced incompetence in the deep venous system; or iv) isolated venous outflow obstruction. These theoretical assumptions have not yet been investigated. The aim of this study was to evaluate patients with superficial and/or deep incompetence and/or venous obstruction with DUS, SGP with selective venous occlusion, venous occlusion plethysmography and radiological imaging. We hypothesized that significant improvement in refilling time after selective venous occlusion would occur in patients with predominantly superficial reflux. Further, we hypothesized that the absent of significant improvements in refilling times after selective venous occlusion could indicate combined deep and superficial reflux with deep vessel dominance and/or venous outflow obstruction.

Material and Methods

Twelve patients (fourteen limbs) were retrospectively assessed in the present study. All patients had been examined with DUS, SGP with superficial venous occlusion and venous occlusion plethysmography as part of the clinical investigation. Radiological imaging had been performed in eight of these patients (ten limbs). Disease severity was C3-C5, according to C in the Clinical Etiology Anatomy Pathophysiology classification (CEAP) [6]. In addition, eleven healthy controls (C0, 11 limbs) were included and evaluated with SGP with superficial venous occlusion only. None of the controls suffered from venous disease, information assessed by history and clinical inspections. Demographic data is shown in Table 1. The study was approved by the regional ethical review board in Linköping, Sweden, and all subjects signed a written informed consent in accordance with the declaration of Helsinki.

Duplex ultrasound

DUS examinations were performed with an ACUSON S2000 ultrasound system (Siemens Medical Solutions, Malvern, PA, USA), using an 18 and 9 MHz transducer. The examination comprised of a standardized protocol to assess reflux in superficial, perforator and deep veins. Presence of normal/abnormal phasic flow during breathing in the common femoral vein was evaluated. A standardized cuff unit (Ekman Biochemical Data AB, Gothenburg, Sweden) inflated to 100 mmHg was used for distal compression and rapid release. Great saphenous vein incompetence was classified according to initial reflux flow during one second after release of distal compression and measured in ml/min in the proximal part of the GSV. This classification is based on data correlating peak flow velocity and volume flow with venous hemodynamics [7-9]. Great saphenous vein incompetence was defined as severe (>100 ml/min and/or a maximal flow velocity of >30 cm/s), moderate (30 mL/min to 100 mL/min and/or <30 cm/s), or mild (<30 mL/min) [7]. Deep venous reflux was considered present if retrograde flow >0.5 sec was detected in the deep femoral vein or the tibioperoneal segment >1 sec in the common femoral vein, femoral vein or the popliteal vein [1]. To avoid the possible confounding effect of superficial incompetence overflow during the examination of the deep venous system care was taken not to evaluate vein segments in the close proximity of the inflow of small saphenous vein or incompetent perforators. Deep venous reflux was classified during DUS in accordance with Lim et al. [10], i.e. axial reflux was classified in five different levels: level 0, no axial reflux; level 1, common femoral vein; level 2, common femoral vein + femoral vein; level 3, common femoral vein + femoral vein + popliteal vein; level 4, common femoral vein + femoral vein + popliteal vein + tibioperoneal segment. Segmental reflux was classified in three different levels: Single level being individual levels of femoral vein, popliteal vein or tibioperoneal segment; multilevel being combinations of femoral vein, popliteal vein or tibioperoneal segment; mixed being level 1 or 2 axial reflux with single or multilevel segmental reflux distal to the common femoral vein [10].

Strain gauge plethysmography with selective superficial occlusion

Evaluation of venous reflux was conducted with our SGP protocol with selective occlusion of superficial veins, which previously has been described and validated by ascending phlebology [5,8]. In short, a strain-gauge was placed around the forefoot and compression cuffs were applied just over the malleoli and below the tibial condyles (Figure 1). Patients performed 20 knee bends at one sec intervals, which activate the calf muscle and the foot pump [11]. After the knee bends the patient remained still until a new steady-state volume was achieved. The time in seconds required to reach 50% (T_{50}) and 90% (T_{90}) of the venous volume were measured and used in the evaluation of venous reflux. The procedure was repeated with individualized cuff pressure to achieve superficial occlusion.

The inflated pressures for the ankle and calf cuffs to achieve selective superficial occlusion were separately calculated for each individual. These calculations are based on earlier experimental data demonstrating that an ankle and calf pressure of 30 mmHg respectively 60 mmHg occludes the superficial system [12]. The original evaluations of the pressures providing selective occlusion of the superficial veins were conducted in supine position with a measuring point 30 cm over heart level. Therefore, corrections for the individual hydrostatic pressure are needed for both cuffs since these are used to occlude superficial veins in the standing position. This was done by adding a hydrostatic column of 30 cm, as well as the individual hydrostatic column in the standing position (the distance between heart level and respective cuff) to the ankle and calf pressure [12]. A conversion factor from cmH2O to mmHg of 0.76 was used. Thus, ankle cuff pressure was calculated as 30 mmHg + (30 cm × 0.76) + the hydrostatic pressure in standing position (cm × 0.76), and calf pressure was calculated as 60 mmHg + (30 cm × 0.76) + the hydrostatic pressure in standing position (cm × 0.76).

Previous evaluation of the method variability has demonstrated that the coefficient of variation for T_{50} and T_{90} are 16% respectively 18% [5]. The methodological error, i.e., the value that can be used to estimate when a change in refilling time between two measurements is probable to reflect a true alteration, has been set to >5 sec for T_{50}, and >14 sec for T_{90} [5,8]. Figures 2A-2C depicts different types of SGP curves.

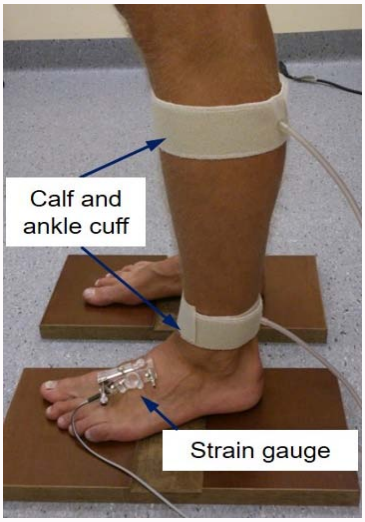

Figure 1: Methodological set-up of distal Strain Gauge Plethysmography (SGP) with calf cuff, ankle cuff and strain gauge to evaluate venous incompetence.

DUS demonstrated an incompetent great saphenous vein below the knee and small saphenous vein incompetence as well as axial level 4 deep venous incompetence. Additionally, angiography also reviled two AV-fistulas in minor branches of a. tibialis anterior and posterior.

Venous occlusion plethysmography

Measurements of venous volume and outflow were performed using a SGP plethysmograph (Bergenheim, Elektromedicin, Göteborg, Sweden). Patients were in supine position with the heels resting on a support 30 cm above heart level and with their knees in approximately 90° angle. Thigh occlusion cuffs were placed on both legs and strain gauges were positioned around the largest part of each calf and mechanically calibrated. The occlusion cuffs were inflated to 60 mmHg during six min at which the pressure was rapidly released. Venous filling volume (VV, ml/100 ml) and venous outflow rate during the first sec (VOV, ml/100 ml/min) were calculated (Figure 3). Signs of venous obstruction were considered to be present if any of the above parameters were below previously published reference values [13]. All SGP data were recorded stored and analyzed using PeriVasc Software (Ekman Biomedical Data AB, Göteborg, Sweden).

Radiological imaging

Imaging was performed as part of the clinical work-up with modalities and protocols chosen according to information in the request. Three patients had Computed Tomography (CT) (Siemens Somatom Force, Definition AS Plus or Drive, Siemens Healthcare GmbH, Erlangen, Deutschland)and seven had Magnetic Resonance Imaging (MRI) (Philips Ingenia Rev 1,5 or 3T, Philips Healthcare, Eindhoven, Netherlands), i.e., two had both. CT and MRI were contrast enhanced. CT imaging was performed in venous contrast phase for evaluation of obstruction or compression. All MRI examinations but one included abdominal dynamic angiography from arterial to late venous phase including pelvic and gonadal veins, and sometimes the upper thighs, for evaluation of direction of flow. Potential obstruction and compression were evaluated in high-resolution images in steady state contrast phase.

Statistics

Statistical analyses were performed using SPSS statistics 27 for Windows (IBM, Armonk, NY, USA). Mann-Whitney U-test was used to compare differences between groups. Statistical significance was defined at $p<0.05$.

Results

DUS

Table 2 shows DUS classification of superficial and/or deep venous incompetence as well as previous interventions and deep venous thrombosis. Five limbs demonstrated superficial reflux (No. 3, 7, 10, 11, 12), one presented with deep reflux (No. 2), three demonstrated combined deep and superficial reflux (No. 4, 5, 6) and five showed no superficial or deep incompetence (No. 1, 8, 9, 13, 14). Reduced respiratory flow phasicity in common femoral vein was detected in four limbs (No. 1, 2, 5, 8).

SGP, Venous occlusion plethysmography and radiological imaging

None of the healthy controls showed any significant changes in either T_{50} or T_{90} after superficial occlusion. The median (min – max) change was -2 (-5–4) sec for T_{50} and 1 (-14–12) sec for T_{90}.

Five limbs were diagnosed with isolated superficial reflux according to DUS (No. 3, 7, 10, 11 and 12). In patients with superficial reflux, the improvement in both T_{50} and T_{90}, after superficial occlusion, was more pronounced compared to controls (T_{50}, p=0.003; T_{90}, p=0.038). The median (min-max) change was 23 (2 to 43) sec for T_{50} and 36 (-6–81) sec for T_{90}. Two of these limbs showed no significant improvement in T_{50} or T_{90} after superficial occlusion (No. 3, 12). However, both limbs demonstrated essentially normal refilling times already before superficial occlusion (T_{50}: 31 and 51 sec; T_{90}: 75 and 118 sec) and DUS demonstrated moderate great saphenous vein reflux in the former and mild great saphenous vein reflux in the latter. Venous occlusion plethysmography showed a possible outflow obstruction in one limb (No. 3) but following imaging found no obstruction (Table 3).

One limb was diagnosed with deep venous reflux according to DUS (No. 2). No significant improvement in refilling times after selective occlusion was detected. Venous occlusion plethysmography showed clear signs of outflow obstruction (Table 3). Radiological imaging was not performed.

Three limbs were diagnosed with combined deep and superficial reflux according to DUS (No. 4, 5, 6). No significant improvements in refilling times after venous occlusion were seen. The first displayed small saphenous vein incompetence and multilevel deep incompetence, the second great saphenous vein incompetence and axial level 2 deep incompetence and the third great and small saphenous vein incompetence as well as the most extensive form of deep axial level 4 reflux. Venous occlusion plethysmography showed signs of outflow obstruction in two of these limbs (No. 4, 5), which was confirmed by imaging (Table 3). Angiography also revealed two arteriovenous fistulas in minor branches of a. tibialis anterior and posterior in limb No. 6.

Five limbs demonstrated no incompetence when evaluated with DUS (No. 1, 8, 9, 13, 14), and the median (min-max) changes in

Table 1: Demographic and clinical data.

	Patients	Controls
n, (limbs)	12 (14)	11 (11)
Mean age (range), yr.	49 (28-67)	38 (22-52)
Women/Men	8/4	5/6

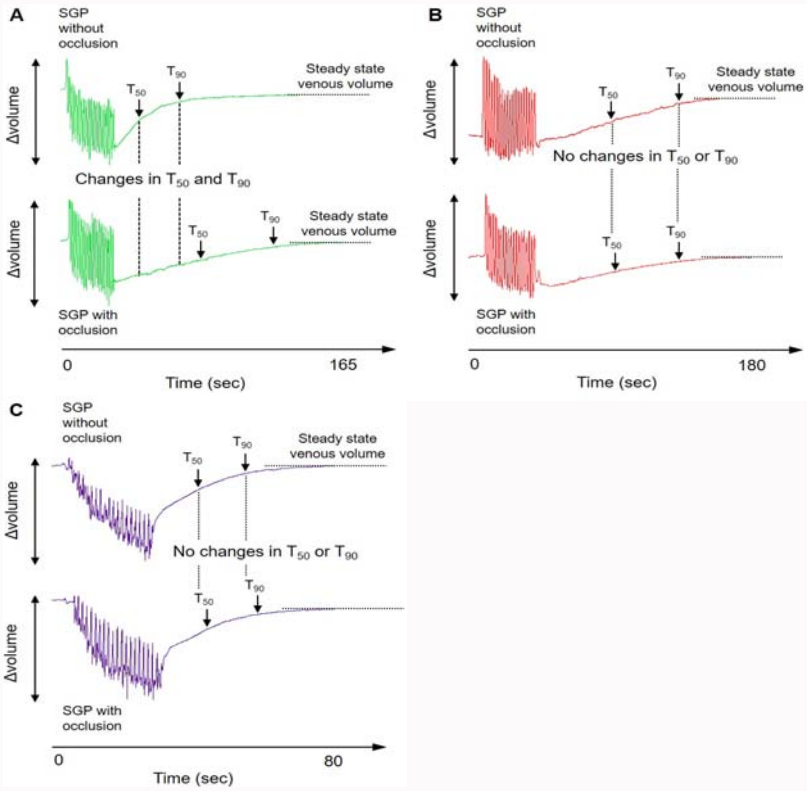

Figure 2: Representative tracings from three patients during distal SGP without and with superficial occlusion. A: Patient with superficial incompetence in which T_{50} and T_{90} improved with 43 respectively 81 sec after superficial occlusion. B: Patient with May Thurner syndrome where no changes in T_{50} (4 sec) or T_{90} (0 sec) were detected after superficial occlusion. C: Patient with superficial and deep venous incompetence where no changes in T50 (1 sec) or T90 (4 sec) were detected when superficial occlusion was applied.

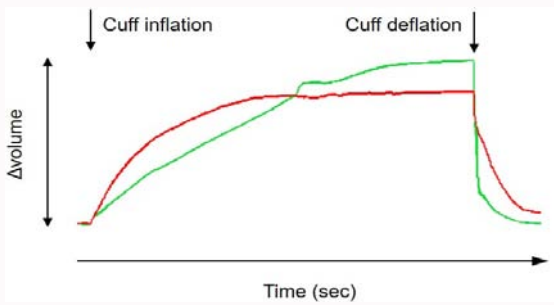

Figure 3: Representative tracings from venous occlusion plethysmography for evaluation of venous outflow obstruction in a patient with May Thurner syndrome. The red curve (left limb) presented decreased venous outflow rate during the first sec (VOV, ml/100 ml/min) after deflation.

T_{50} and T_{90} after superficial occlusion were 0 (-5-9) and 0 (-8-4) sec, respectively. The calculated changes for T_{50} and T_{90} were similar to those found in healthy controls (T_{50}, p=0.83; T_{90}, p=0.91). Four of the five limbs showed no significant changes in T_{50} or T_{90} after superficial occlusion. In one limb (No. 8), the change in T_{50} was one sec above the predetermined methodological error, whereas the change in T_{90} was within the methodological error. Venous occlusion plethysmography displayed signs of outflow obstruction in one limb (No. 14), which was confirmed by imaging. Further, imaging showed venous obstruction in additional three limbs (No. 1, 8 and 13, Table 3).

Finally, one patient (No. 9) showed varicose/incompetent pelvic and ovarian veins and was diagnosed with pelvic congestion syndrome based on the combination of clinical and radiological findings (Table 3). Figure 4A, 4B summarize each patient diagnose based on DUS, venous occlusion plethysmography and imaging with corresponding changes in T_{50} and T_{90} after superficial occlusion.

Lastly, radiological imagining confirmed outflow obstruction in all limbs with depressed respiratory phasic flow during DUS (No. 1, 5, 8). However, three limbs without obvious reduced respiratory phasic flow displayed outflow obstruction during imaging (No. 4, 13, 14).

Discussion

The present study supported the general assumptions that distal SGP with standardized superficial venous occlusion can be a useful technique to quantify the hemodynamic significance of the superficial component of reflux in relation to deep venous incompetence or venous obstruction.

Although DUS is considered to be gold standard in the diagnosis of chronic venous disease, it does not permit an overall quantification of venous function [1]. Current practice depends on that the anatomical identification of reflux with DUS will guide physicians to the best treatment option. In this context, hemodynamic evaluations have been considered surrogate endpoints. However, some patients describe no subjective improvement despite successful ablation and it is not always easy to determine if symptoms are venous or non-venous in its origin [4,14]. Thus, in some cases it seems that a hemodynamic evaluation could be of importance to ascertain the patient's symptomatology. Plethysmography is mentioned in guidelines as a complement to assess quantitative parameters when needed, or for additional evaluation if DUS does not provide complete information on the pathophysiology [1,15]. Assessment of venous reflux by using compression cuffs to occlude superficial

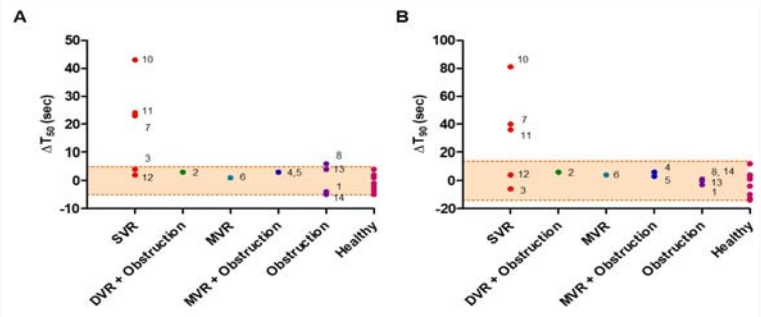

Figure 4: Changes in refilling times between Strain Gauge Plethysmography (SGP) with and without superficial occlusion separated by diagnosis. A: T_{50}. B: T_{90}. The filled area represents the time interval for no significant changes between SGP with and without superficial occlusion.

Table 2: DUS findings and previous clinical history.

Limb	C in CEAP	Previous intervention		Superficial venous reflux (ml/min)			Perforator (n)	Deep venous reflux					Previous DVT
No.	C	GSV	SSV	GSV	Accessory branch	SSV		CFV	FV	PV	TPT	Axial/ Segmental	
2	5	No	No	0	0	0	0	Yes	Yes	No	Yes	Mixed	Yes
3	3	No	No	70	0	0	0	No	No	No	No	No	No
4	3	Yes	No	0	Yes	160	1	No	Yes	Yes	Yes	Multilevel	Yes
5	3	No	No	>100	0	0	0	Yes	Yes	No	No	Axial level 2	Yes
6	4	Yes	No	170*	0	260	1	Yes	Yes	Yes	Yes	Axial level 4	No
7	3	No	No	0	Yes	0	1	No	No	No	No	No	No
8	3	No	No	0	0	0	0	No	No	No	No	No	No
9	3	Yes	Yes	0	0	0	0	No	No	No	No	No	No
10	3	Yes	No	0	Yes	40	2	No	No	No	No	No	No
11	4	No	No	100	0	0	0	No	No	No	No	No	No
12	3	No	No	27	0	0	0	No	No	No	No	No	No
13	4	No	No	0	0	0	0	No	No	No	No	No	No
14	3	No	No	0	0	0	0	No	No	No	No	No	No

CEAP: Clinical Etiology Anatomy Pathophysiology; GSV; Great Saphenous Vein; SSV; Small Saphenous Vein; CFV; Common Femoral Vein; FV: Femoral Vein; PV: Popliteal Vein; TPT: Tibioperoneal Segment; DVT: Deep Venous Thrombosis
*Below the knee

veins has been used to differentiate superficial and deep venous incompetence, although the results have been conflicting which is probably due to lack of consensus about the use of compression cuffs [16-18]. We have recently developed a standardized SGP model with selective occlusion of the superficial veins, which has been validated by ascending phlebology [5,8,12]. With our model, it is possible to predict the hemodynamic improvements after radiofrequency ablation in patients with isolated great saphenous vein incompetence [5].

In the present study, none of the healthy controls displayed any significant changes in either T_{50} or T_{90} after superficial occlusion, further implying that our model with selective occlusion is a reliable method to evaluate if superficial incompetence is the predominate hemodynamic factor in a patient with symptoms form the lower limb. Five limbs were diagnosed with isolated superficial reflux based on DUS. As expected, these patients' improvements in both T_{50} and T_{90}, after superficial occlusion, were more pronounced than healthy controls. Nonetheless, two patients did not show significantly improvements in refilling times after superficial occlusion. Both these patients demonstrated essentially normal refilling times before occlusion suggesting a mild superficial reflux that would not obviously be associated with improved venous hemodynamic function after intervention against superficial veins.

Predicting the hemodynamic outcome after intervention may be of special importance in patients with combined deep and superficial reflux. There is today no established method that can quantify the contribution of the reflux in the two compartments in relation to each other, and, in certain patients, it might therefore be difficult to evaluate whether the patient will benefit from invasive treatment. Current guidelines suggest that these patients primarily should be treated with intervention targeting the superficial component and if this results in clinical failure, despite adequate compression therapy, deep venous reconstruction should be considered [1,19]. The ESCHAR trial supported the addition of superficial venous intervention irrespective of the presence or absence of deep vein reflux in patients with ulcers [20]. However, it is not certain that all patients with concomitant superficial and deep incompetence benefit from superficial intervention, and not all patients with combined superficial and deep reflux have ulcers. For example, Marston et al. [21] found significant clinical and hemodynamic improvement when the deep venous reflux had a maximum reflux velocity of 10 cm/s or less, whereas limbs with higher maximum reflux velocity were more rarely found to normalize venous hemodynamics or venous clinical severity score post ablation. A recent study also demonstrated that patients with combined deep and superficial reflux have a significantly increased rate of postoperative complications, including proximal thrombus extension, after endovenous truncal ablation [22]. It is a

Table 3: Venous occlusion plethysmography assessment and radiological imaging of venous outflow obstruction.

Limb	Venous occlusion plethysmography		Radiological imaging
No.	VOV (ml/100 ml/min) Ref. values 62-158 (13).	VOV, difference (ml/100 ml/min) Ref. values <38 (13).	MRI or CT
1	78	-28	Compression EIV
2	30	-180	Not performed
3	58	-52	No obstruction
4	64	-41	Post thrombotic stenosis CIV
5	42	-36	May-Thurner
6	208	110	No obstruction
7	95	-44	No obstruction
8	140	44	May Thurner
9	83	-2	Varicose/incompetent pelvic and ovarian veins
10	65	-23	Not performed
11	120	-13	Not performed
12	77	-3	No obstruction
13	81	3	May Thurner and unclear IVC stenosis
14	153	-109	Post thrombotic stenosis CFV

Difference, difference between the two limbs; VOV: Venous Outflow rate during the first sec; MRI: Magnetic Resonance Imaging; CT: Computed Tomography; EIV: External Iliac Vein; CIV: Common Iliac Vein; CFV: Common Femoral Vein; IVC: Inferior Vena Cava

possibility that DUS detected deep reflux sometimes is driven by a secondary overflow into the deep veins by superficial incompetence via perforators or small saphenous vein. This type of combined deep and superficial reflux would arguably show an improvement in refilling times after superficial occlusion and would also be helped by treatment of superficial veins. In our study, three limbs were diagnosed with combined deep and superficial reflux based on DUS. None of these limbs showed any significant improvement in refilling times after superficial occlusion, suggesting that superficial treatment would not lead to improved venous hemodynamics. It is important to note that, due to small sample size and no post-operative follow up, these clinical implications need to be tested in larger prospective studies. Nevertheless, it is important to develop quantitative hemodynamic tests for patients with chronic venous disease to help clinical decision-making, and our developed SGP technique with selective venous occlusion seems to be one potential method.

It is also important to note that the lack of improvement in refilling times may indicate a proximal outflow obstruction, which is not uncommon in patients with reflux [4]. In the one limb with deep incompetence, and the three limbs with combined deep and superficial reflux, additional diagnostics demonstrated outflow obstruction in three cases. The reason for the lack of improvement in refilling time in patients with combined deep and superficial reflux and venous obstruction are possibly twofold. Firstly, the deep incompetence may be so pronounced, in comparison to the superficial incompetence, that the total burden of reflux will not significantly change after selective superficial occlusion. Secondly, the intravenous pressure, during the knee bends, will probably increase due to hampered venous outflow [23], which may lead to incomplete superficial occlusion and thus underestimation of the superficial reflux component.

Diagnosing venous outflow obstruction is important but identification of proximal venous obstruction using DUS is typically limited [24] and it has recently been shown that approximately 15% of patients treated with venous stenting due to outflow obstruction had an earlier history of endovenous ablation of superficial veins with remaining symptoms after intervention [4]. Plethysmographic investigations have been used to quantify global venous function although standard measurements such as total venous volume, outflow volume and outflow fraction has been demonstrated to have a too low discriminatory value for clinical use [25]. Since our venous occlusion plethysmography findings were based on outflow volume, they should as such be interpreted with care. Based on this, the diagnosis venous obstruction was always confirmed with radiological imagining, except for limb No. 2. It should be noted that MRI may help to localize the site of the obstruction, but does not provide any hemodynamic information, and there is a need for hemodynamic tests so treatment of outflow obstruction is not based on anatomical findings alone [26,27]. Newer plethysmographic parameters may be more valuable in identifying hemodynamic relevant obstructions, e.g., the venous drainage index or lower limb outflow resistance [28,29].

In the present study, five patients presented with no venous incompetence according to DUS, and the changes in T_{50} and T_{90}, after superficial occlusion, did not differ from those seen in healthy controls. Of the five limbs, four showed no significant changes in T_{50} or T_{90} after superficial occlusion. In one limb, the change in T_{50} was just above the predetermined methodological error but no change in T_{90} was noted. Subsequent radiological imaging displayed outflow obstruction in all limbs, except one, in which imaging combined with clinical symptoms led to the diagnosis pelvic congestion syndrome. This suggest that patients with lower limb symptoms who do not improve their refilling times after superficial occlusion, whether they are diagnosed with superficial, deep, mixed or no venous reflux during DUS, should be considered for evaluation of possible proximal outflow obstruction.

Some limitations are worth mentioning. This was a small retrospective pilot study designed to test the theoretical assumptions that distal SGP with selective venous occlusion could accurately separate a hemodynamically significant superficial component of reflux from a deep component of reflux or venous obstruction.

The potential clinical benefits regarding proper patient selection for interventional treatment needs to be evaluated in prospective studies with larger and more homogenous patient materials. Further, those studies need to include postoperative evaluation of both hemodynamic parameters and clinical outcomes.

Conclusion

Distal SGP with selective venous occlusion seems to have the potential to quantify the superficial component of reflux in relation to deep venous reflux or venous obstruction.

Author Contributions

HZ and JS conceived the study. JS, ON, MA and HZ analyzed and/or interpreted the data. JS wrote the first draft of the manuscript. All authors reviewed and revised the manuscript for intellectual content and approved the final manuscript.

Funding

This research was funded by ALF Grants, Region Ostergotland [LIO-932453].

References

1. Wittens C, Davies AH, Baekgaard N, Broholm R, Cavezzi A, Chastanet S, et al. Editor's choice - management of chronic venous disease: Clinical practice guidelines of the European Society for Vascular Surgery (ESVS). Eur J Vasc Endovasc Surg. 2015;49(6):678-737.
2. Ascher E, Eisenberg J, Bauer N, Marks N, Hingorani A, Rizvi S. The bull's eye sign and other suprainguinal venographic findings to limit the use of intravascular ultrasound in patients with severe venous stasis. J Vasc Surg Venous Lymphat Disord. 2017;5(1):70-4.
3. Radaideh Q, Patel NM, Shammas NW. Iliac vein compression: Epidemiology, diagnosis and treatment. Vasc Health Risk Manag. 2019;15:115-22.
4. Chait J, Chapman EK, Subramaniam S, Chun K, Vouyouka AG, Tadros R, et al. Persistent symptoms after endovenous thermal ablation may suggest proximal venous outflow obstruction. J Vasc Surg Venous Lymphat Disord. 2020;8(2):231-6.
5. Nelzen PO, Skoog J, Lassvik C, Lanne T, Zachrisson H. Prediction of post-interventional outcome in great saphenous vein incompetence: The role of venous plethysmography with selective superficial vein occlusion. Eur J Vasc Endovasc Surg. 2016;52(3):377-84.
6. Lurie F, Passman M, Meisner M, Dalsing M, Masuda E, Welch H, et al. The 2020 update of the CEAP classification system and reporting standards. J Vasc Surg Venous Lymphat Disord. 2020;8(3):342-52.
7. Zachrisson H, Nelzén O, Lassvik C, Skoog J. Estimation of superficial venous reflux with duplex ultrasound and foot volumetry. JOJ Case Stud. 2019;10(1):1-5.
8. Nelzén POE, Skoog J, Öster M, Zachrisson H. Impact on venous haemodynamics after treatment of great saphenous vein incompetence using plethysmography and duplex ultrasound. Phlebology. 2020;35(7):495-504.
9. Yamaki T, Nozaki M, Sakurai H, Takeuchi M, Kono T, Soejima K. Quantification of venous reflux parameters using duplex scanning and air plethysmography. Phlebology. 2007;22(1):20-8.
10. Lim KH, Hill G, Tarr G, van Rij A. Deep venous reflux definitions and associated clinical and physiological significance. J Vasc Surg Venous Lymphat Disord. 2013;1(4):325-32.
11. Recek C. Calf pump activity influencing venous hemodynamics in the lower extremity. Int J Angiol. 2013;22(01):023-30.
12. Zachrisson H, Volkmann R, Bergerheim T, Holm J. Selectivity of superficial vein occlusion at the ankle and calf level: A methodological study in healthy volunteers. Clin Physiol. 1998;18(1):55-60.
13. Rosfors S, Persson LM, Blomgren L. Computerized venous strain-gauge plethysmography is a reliable method for measuring venous function. Eur J Vasc Endovasc Surg. 2014;47(1):81-6.
14. Lattimer CR, Rudolphi PB, Recke A, Geroulakos G, Kalodiki E, Kahle BK. Comparison of four haemodynamic tests that quantify superficial venous insufficiency. Eur J Vasc Endovasc Surg. 2019;57(4):570-7.
15. Gloviczki P, Comerota AJ, Dalsing MC, Eklof BG, Gillespie DL, Gloviczki ML, et al. The care of patients with varicose veins and associated chronic venous diseases: Clinical practice guidelines of the Society for Vascular Surgery and the American Venous Forum. J Vasc Surg. 2011;53(5 Suppl):2S-48S.
16. Skeik N, Kalsi H, Wysokinski WE, Heaser TV, Wennberg PW. Predicting superficial venous incompetence with strain gauge plethysmography. Phlebology. 2012;27(3):135-40.
17. Criado E, Farber MA, Marston WA, Daniel PF, Burnham CB, Keagy BA. The role of air plethysmography in the diagnosis of chronic venous insufficiency. J Vasc Surg. 1998;27(4):660-70.
18. Harada RN, Katz ML, Comerota A. A noninvasive screening test to detect "critical" deep venous reflux. J Vasc Surg. 1995;22(5):532-7.
19. Maleti O, Perrin M. Reconstructive surgery for deep vein reflux in the lower limbs: Techniques, results and indications. Eur J Vasc Endovasc Surg. 2011;41(6):837-48.
20. Barwell JR, Davies CE, Deacon J, Harvey K, Minor J, Sassano A, et al. Comparison of surgery and compression with compression alone in chronic venous ulceration (ESCHAR study): Randomised controlled trial. The Lancet. 2004;363(9424):1854-9.
21. Marston WA, Brabham VW, Mendes R, Berndt D, Weiner M, Keagy B. The importance of deep venous reflux velocity as a determinant of outcome in patients with combined superficial and deep venous reflux treated with endovenous saphenous ablation. J Vasc Surg. 2008;48(2):400-5; discussion 5-6.
22. Brown CS, Osborne NH, Kim GY, Sutzko DC, Wakefield TW, Obi AT, et al. Effect of concomitant deep venous reflux on truncal endovenous ablation outcomes in the vascular quality initiative. J Vasc Surg Venous Lymphat Disord. 2021;9(2):361-8.e3.
23. Kurstjens RLM, de Wolf MAF, Konijn HW, Toonder IM, Nelemans PJ, de Graaf R, et al. Intravenous pressure changes in patients with postthrombotic deep venous obstruction: Results using a treadmill stress test. J Thromb Haemost. 2016;14(6):1163-70.
24. Hui JZ, Goldman RE, Mabud TS, Arendt VA, Kuo WT, Hofmann LV. Diagnostic performance of lower extremity Doppler ultrasound in detecting iliocaval obstruction. J Vasc Surg Venous Lymphat Disord. 2020;8(5):821-30.
25. Kurstjens RL, Catarinella FS, Lam YL, de Wolf MA, Toonder IM, Wittens CH. The inability of venous occlusion air plethysmography to identify patients who will benefit from stenting of deep venous obstruction. Phlebology. 2018;33(7):483-91.
26. Esposito A, Charisis N, Kantarovsky A, Uhl JF, Labropoulos N. A comprehensive review of the pathophysiology and clinical importance of iliac vein obstruction. Eur J Vasc Endovasc Surg. 2020;60(1):118-25.
27. Kakkos SK, Black SA. Assessment and interpretation of common iliac vein occlusive pathology. Eur J Vasc Endovasc Surg. 2020;60(1):126.
28. Lattimer CR, Doucet S, Geroulakos G, Kalodiki E. Validation of the novel venous drainage index with stepwise increases in thigh compression pressure in the quantification of venous obstruction. J Vasc Surg Venous Lymphat Disord. 2017;5(1):88-95.
29. Nicolaides A, Maleti O, Lugli M, Guerzoni S. Noninvasive measurement of lower limb outflow resistance and implications for stenting. Vasc Investig Ther. 2019;2(4):88-94.