



Diaphragmatic Laceration Following Penetrating Thoracic Trauma

Heping Huang^{1*}, Qianlun Huo¹, Jianzhong Ma² and Zhengwu Zhou²

¹Department of Cardiothoracic Surgery, The Lu'an Affiliated Hospital, Anhui Medical University, China

²Department of Emergency Surgery, The Lu'an Affiliated Hospital, Anhui Medical University, China

Abstract

Background: The management of diaphragmatic laceration and penetrating thoracic trauma represents a major challenge for emergency department staff, which is easily delayed and missed on initial assessment and diagnosis in a limited timeframe. Therefore, it is obviously difficult to diagnose diaphragmatic rupture promptly and accurately in the setting of penetration injury.

Case Presentation: We reported the patient, a 33-year-old man with consciousness, was stabbed in his back dorsal region paravertebrally. The patient underwent the prompt exploratory thoracotomy, intraoperative findings revealed a diaphragmatic laceration with acute bleeding. He was discharged on postoperative day 7 without any complications.

Conclusion: There should be a low threshold for performing exploratory procedures when cases are highly suspicious for diaphragmatic injuries following penetrating thoracic trauma.

Keywords: Diaphragmatic laceration; Penetrating thoracic trauma; Diaphragmatic repair; Stab wound

Introduction

Penetrating thoracic trauma management represents a major problem for emergency managements. Cause of penetrating injuries of the dorsal regions may be bullets or other penetrating sharp objects. Penetrating thoracic traumas have a wide spectrum, ranging from mild traumas to life-threatening injuries. Penetrating injury is usually the result of the abrupt, direct application of a mechanical force to a focal area. The severity of the internal injury depends on the depth of the puncture and the importance of organs.

Diaphragmatic rupture is an uncommon and potentially serious complication following penetrating trauma. Preoperative diagnosis of diaphragmatic injury is still a real diagnostic challenge. We reported the patient was stabbed in his back dorsal region paravertebrally, and the exploratory thoracotomy showed a diaphragmatic rupture with active bleeding. Furthermore, we aim to increase physicians' awareness of this rare and life-threatening case.

Case Presentation

The patient, a 33-year-old man with consciousness, was referred to our emergency department after being stabbed in his back, his hemodynamics was stable. A knife pierced thorax from the dorsal region paravertebrally (Figure 1a), the bedside X-ray showed no rib fracture, pneumothorax and hemothorax were found (Figure 1b). Under general anesthesia, the knife fell off the back due to local tissue of the wound relaxed before exploratory thoracotomy (Figure 2a). Moreover, open pneumothorax was recognized by drifting the air through the wound and synchronously with breathing. The patient underwent left lateral minithoracotomy through the approach of the eighth intercostal space. Intraoperative findings revealed a diaphragmatic laceration with active oozing because of injury caused by the knife (Figure 2b). The diaphragmatic wound is approximately 15 mm in size, but it did not enter into the abdominal cavity. Diaphragm muscle was preferentially sutured with 2/0 mersilk to effective hemostasis, and subcutaneous drainage and pressure dressing was applied on the wound. The patient was uneventful after the operation who was discharged on postoperative day 7. Furthermore, the patient was well without any complications during six months of follow-up.

Discussion and Conclusion

The increased prevalence of penetrating chest injury and improved prehospital and perioperative

OPEN ACCESS

*Correspondence:

Heping Huang, Department of Cardiothoracic Surgery, The Lu'an Affiliated Hospital, Anhui Medical University, No. 21, Wanxi West Road, Lu'an City, Anhui Province, 237005, China, Tel: +86-5643597074; Fax: +86-5643338627;

E-mail: peacehuang@126.com

Received Date: 20 Jan 2020

Accepted Date: 13 Feb 2020

Published Date: 18 Feb 2020

Citation:

Huang H, Huo Q, Ma J, Zhou Z. Diaphragmatic Laceration Following Penetrating Thoracic Trauma. Clin Surg. 2020; 5: 2742.

Copyright © 2020 Heping Huang. This is an open access article distributed under the Creative Commons Attribution License, which permits unrestricted use, distribution, and reproduction in any medium, provided the original work is properly cited.

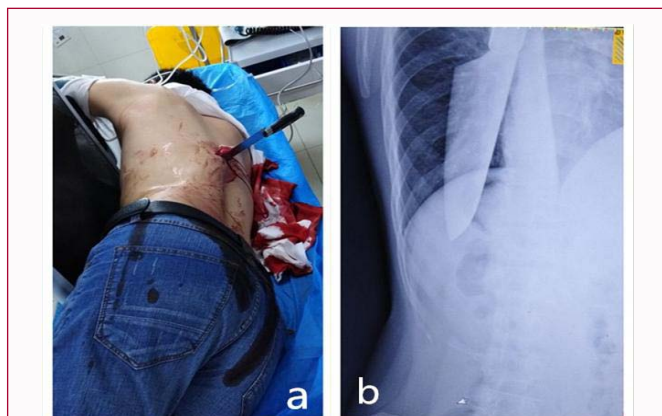


Figure 1: (a) The site and pattern of stabbing, a knife pierced thorax from dorsal region paravertebrally. (b) The bedside emergency X-ray showed no rib fracture, pneumothorax and hemothorax was seen.

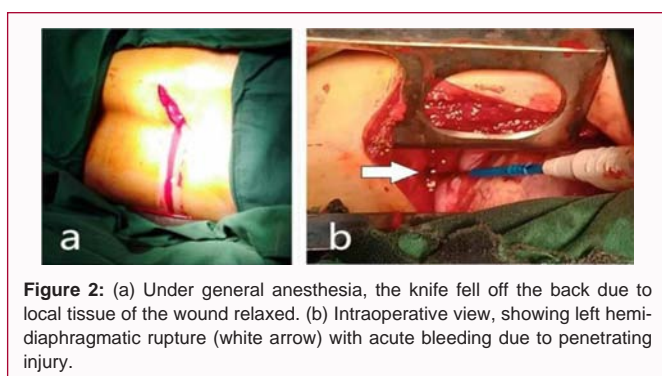


Figure 2: (a) Under general anesthesia, the knife fell off the back due to local tissue of the wound relaxed. (b) Intraoperative view, showing left hemidiaphragmatic rupture (white arrow) with acute bleeding due to penetrating injury.

care have resulted in an increasing number of critically injured, so potentially salvageable patients presenting to trauma centers [1]. Thoracic traumas may be a life-threatening condition, which should be identified and treated immediately. Mortality varies based on etiological factors, additional systemic pathologies, capabilities of the hospital especially diagnostic and treatment facilities in emergency services.

Trauma with penetrating dorsal thoracic injuries is usually in the form of stabbing, sharp penetrating object injuries. The key point of a successful trauma management is to determine whether a life-threatening condition exists. The general rules of penetrating trauma management are to avoid in-depth exploration for wound site assessment, to avoid removal of penetrating object without accurate diagnosis, and to keep in mind the possibility of intubation for airway security in every moment.

Clinical manifestation of stabbing wound is painful at the point of stabbing, irritation cough and short breath. After taking out the stabbing object from the wound, profuse bleeding is usually present and sometimes wheezing from the suction wound. Blood clot and transected tissue from the chest wall can cover the stabbing wound, which would convert open pneumothorax to tension pneumothorax [2].

During the initial care of patients with penetrating trauma, the object should not be abruptly removed from its place in order to avoid any secondary trauma before surgical intervention. Our case was also brought to our attention without moving the knife from its position and the patient was rapidly assessed and taken into the operating

room. Video assisted thoracic surgery is less likely to be feasible for a complicated emergency exploration, thus an open approach was felt to be the safest and most effective method of surgery.

The severity of stab wounds depends on the pierce point to the chest accompanying with organ injure (chest wall vessels, lung, heart, great thoracic vessels, visceral pleura, esophagus, diaphragm), the shape and sharpness of penetrating object, and whether the penetrating object still remained in the wound or was removed. In most cases, stabbing object penetrates through the chest wall and hurts intercostal blood vessels or visceral pleura, which contributes to the development of pneumothorax or hemopneumothorax [3]. The majority of patient's deaths in penetrating traumas are due to serious vascular injury.

Diaphragmatic rupture is a potentially lethal clinical condition for the patient, and a delayed or missed diagnosis causes high mortality with this type of trauma [4]. Traumatic diaphragmatic laceration with left-sided injuries is more frequently reported than that with right-sided traumas due to the protective nature of the liver, which is easily missed on initial diagnosis. Data from the National Trauma Databank in the USA suggest an occurrence of 0.46% of all traumas, but two-thirds of the injuries were from penetrating trauma [5]. In this case report, the diaphragmatic injury should be concerned because the patient was admitted with a knife still in place.

An early and accurate diagnosis of diaphragmatic injury in the setting of penetrating and blunt trauma can be difficult even with the help of sophisticated diagnostic modalities [6]. Presentation and diagnosis of the diaphragm rupture can be delayed for long periods (between 2 to 26 years in some reports) [7]. Computed tomography is the mainstay in the diagnosis of such injuries, which may be subtle at presentation. However, the current patient did not undergo computed tomography examination instead of bedside chest X-ray because of the critical condition of this case. Diagnosis in trauma is based on clinical suspicion with radiological support; meanwhile, prompt surgical management is required to prevent adverse outcomes. Definitive surgical repair is warranted in all cases of traumatic diaphragmatic rupture even in small defects due to lack of spontaneous healing [8]. Diaphragmatic laceration can result in unstable hemodynamic condition due to massive bleeding of diaphragm, because inferior phrenic artery supplying blood to the diaphragm mainly originates anatomically from the celiac artery trunk and the abdominal aorta with higher blood pressure.

In conclusion, there should be a low threshold for performing exploratory procedures when cases are highly suspicious for diaphragmatic injuries. Exploratory thoracotomy and thoracoscopic evaluation with meticulous examination of diaphragm are the preferred management for diaphragmatic laceration following penetrating trauma. Furthermore, during the initial care of patients with penetrating trauma, the object should not be removed from its place to avoid any secondary trauma.

Declaration of Patient Consent

The authors certify that they have obtained all appropriate patient consent forms. In the form the patient(s) has/have given his/her/their consent for his/her/their images and other clinical information to be reported in the journal. The patients understand that their names and initials will not be published and due efforts will be made to conceal their identity, but anonymity cannot be guaranteed.

References

1. Khandhar SJ, Johnson SB, Calhoon JH. Overview of thoracic trauma in the United States. *Thorac Surg Clin.* 2007;17(1):1-9.
2. Kuhajda I, Zarogoulidis K, Kougioumtzi I, Huang H, Qiang Li, Georgios D, et al. Penetrating Trauma. *J Thorac Dis.* 2014;6(S4):461-5.
3. Asensio JA, Arroyo H, Veloz W, Forno W, Gambaro E, Roldan GA, et al. Penetrating Thoracoabdominal Injuries: Ongoing Dilemma-Which Cavity and When? *World J Surg.* 2002;26(5):539-43.
4. Düzgün AP, Ozmen MM, Saylam B, Coşkun F. Factors Influencing Mortality in Traumatic Ruptures of Diaphragm. *Ulus Travma Acil Cerrahi Derg.* 2008;14(2):132-8.
5. Fair KA, Gordon NT, Barbosa RR, Rowell SE, Watters JM, Schreiber MA. Traumatic diaphragmatic injury in the American College of Surgeons National Trauma Data Bank: A new examination of a rare diagnosis. *Am J Surg.* 2015;209(5):864-8.
6. Petrone P, Asensio JA, Marini CP. Diaphragmatic Injuries and Post-Traumatic Diaphragmatic Hernias. *Curr Probl Surg.* 2017;54(1):11-32.
7. Davoodabadi A, Fakharian E, Mohammadzadeh M, Abdorrahim Kashi E, Mirzadeh AS. Blunt traumatic hernia of diaphragm with late presentation. *Arch Trauma Res.* 2012;1(3):89-92.
8. Ties JS, Peschman JR, Moreno A, Mathiason MA, Kallies KJ, Martin RF. Evolution in the management of traumatic diaphragmatic injuries: A Multicenter Review. *J Trauma Acute Care Surg.* 2014;76(4):1024-8.