Clinics in Surgery

Research Article
Published: 10 Mar, 2020

Complementary Endovascular Procedures Improve Aortic Remodeling in Progressive Chronic Aortic Dissection

*Paul Revel-Mouroz[1], Fatima-Zohra Mokrane[1], Camille Dambrin[2], Christophe Cron[2], Marion Jaffro[1], Bertrand Saint-Lèbes[3], Charline Zadro[1], Philippe Otal[1] and Hervé Rousseau[1]**

[1]Department of Radiology, Hospital Rangueil, Central Hospital University of Toulouse, France

[2]Department of Cardiovascular Surgery, Hospital Rangueil, Central Hospital University of Toulouse, France

[3]Department of Vascular Surgery, Hospital Rangueil, Central Hospital University of Toulouse, France

Abstract

Objective: Residual False Lumen (FL) patency after chronic type A or type B Aortic Dissection (AD) treatment is an independent factor of poor longterm outcome. The aim of this study was to evaluate ancillary endovascular procedures in progressive AD, to improve false lumen thrombosis and aortic remodeling.

Methods: Between August 2005 and December 2017, 59 ancillary endovascular procedures were performed in 35 consecutive patients for aneurysmal expansion, aortic rupture or malperfusion syndrome. Sixteen patients (45.7%) presented an initial type A AD treated by open aortic surgery, and 19 (54.3%) presented a type B AD, previously treated by TEVAR. Aortic remodeling was evaluated on the preprocedural and on the most recent computed tomography angiography follow-up for each patient.

Results: At a median follow-up time of 60.7 months [44.4-76.8], 59 ancillary endovascular procedures were performed. At the end of the follow-up, positive remodeling was obtained in 85.7% of cases with a complete false lumen thrombosis in 9 patients (25.7%), and a diameter reduction or stability (<5 mm increase) in 21 patients (60.0%). The mean total false lumen thrombosis score before the first ancillary procedure was 0.97 (± 0.90) *vs*. 2.54 (± 0.98) at the end of the follow-up, p<0.0001. One patient died of a retrograde dissection, 2 days after a proximal aortic stent graft extension.

Conclusion: Ancillary endovascular procedures are effective and safe to promote aortic remodeling in progressive chronic AD.

Keywords: Aortic dissection; Aortic remodeling; Thoracic endovascuar aneurysm repair; False lumen embolization; Aneurysmal expansion; TEVAR

OPEN ACCESS

***Correspondence:**
Hervé Rousseau, Department of Radiology, Hospital Rangueil, Central Hospital University of Toulouse, Avenue du Pr. Jean Poulhès, TSA 50032, 31059 Toulouse Cedex 9, France, Tel: +33561322252; E-mail: rousseau.h@chu-toulouse.fr

Received Date: *29 Jan 2020*
Accepted Date*: 04 Mar 2020*
Published Date*: 10 Mar 2020*

Citation:
Revel-Mouroz P, Mokrane F-Z, Dambrin C, Cron C, Jaffro M, Saint-Lèbes B, et al. Complementary Endovascular Procedures Improve Aortic Remodeling in Progressive Chronic Aortic Dissection. Clin Surg. 2020; 5: 2756.

Introduction

Aortic Dissection (AD) is one of the most devastating cardiovascular disease. Current international guidelines clearly establish surgery as the treatment of choice for type A AD, whereas Thoracic Endovascular Aneurysm Repair (TEVAR) is the recommended strategy for complicated type B AD [1-3]. There is still some controversy around the treatment of uncomplicated type B aortic dissection. Improved long-term outcomes with TEVAR, especially regarding disease progression and aortic-related mortality, could lead to a next paradigm shift in favor of invasive treatment of uncomplicated subacute type B AD [4].

However, after conventional TEVAR, Complete False Lumen (FL) thrombosis is only achieved in around 40% of the patients by covering the proximal tear entry alone [5]. Moreover, false lumen patency is independently associated with poor long-term survival in chronic TBAD, while thrombosis of the false lumen may be an independent predictor of stabilization of the transaortic diameter and is associated with improved clinical outcomes [6,7].

Thus, persistent perfusion and pressurization of the false lumen by secondary entry tears or endoleaks can lead to late aneurysmal aortic expansion and rupture in 30% of patients treated with TEVAR, requiring additional re-interventions [8,9].

During the last decade, promising additional therapeutic strategies have emerged in order to

improve aortic remodeling, including distal stent-graft extension with bare metal stents for type B AD, branched stent grafts or false lumen embolization to induce false lumen thrombosis [10-15].

In this study, we aimed to evaluate the efficiency and the safety of complementary endovascular procedures performed to overcome incomplete aortic repair in patients with an AD presenting with aneurysmal expansion, aortic rupture or malperfusion syndromes despite the initial conventional treatment.

Methods

Patient population

This study is a retrospective analysis of a prospectively collected database.

Between August 2005 and December 2017, all consecutive patients with an AD treated by at least one complementary endovascular procedure for: i) aneurysmal expansion defined as a transaortic diameter expansion ≥ 4 mm (annualized), ii) aortic rupture or iii) malperfusion syndrome were identified from our prospective registry. All patients gave written informed consent.

Fifty-nine ancillary endovascular procedures were performed in 35 patients. Among 35 patients, 16 (45.7%) presented an initial type A AD treated by conventional aortic surgery, and 19 (54.3%) presented an initial type B AD, treated by conventional TEVAR when complicated, including coverage of the Left Subclavian Artery (LSA) or cervical debranching of the supra-aortic trunks when indicated.

Procedure technique

Interventions were planned and adapted according to the vascular anatomy of each patient. Moreover, frequently, combined procedures were performed to achieve complete false lumen thrombosis.

All procedures were carried out under general anesthesia in a hybrid operative room (Discovery™ IGS 740 angiography system, GE Healthcare). Image fusion technique was used to facilitate the catheterization and to reduce both irradiation and contrast media injection. All FL catheterizations were done through distal re-entry tears at the level of the iliac arteries, the visceral reentries or at the level of the visceral aorta after percutaneous femoral access.

Procedures were classified into 4 groups:

a) Intervention on the true aortic lumen. These interventions concerned any stent-graft for type A AD and proximal or distal extension for type B AD, to close a secondary entry tear of the dissection flap, or type I or III endoleak.

b) Intervention on the true lumen of a collateral artery to close re-entry tears arising from collateral arteries, using covered stents.

c) Direct embolization of the false aortic lumen to promote false lumen thrombosis when persistent perfusion of the false lumen raised from retrograde abdominal re-entries or intercostal or lombar arteries. A large variety of devices as well as liquid embolization materials have been used to occlude the false lumen. Initially to reduce the flow and avoid distal migration of the materials, coils and plugs (Amplatzer Vascular Plug (AVP) Abbott Vascular) were deployed in the FL, generally at the level of the coeliac trunk, completed by glue injection.

d) Intervention on the false lumen of a collateral artery by embolization to seal re-entries or to occlude type 2 endoleak.

Data collection and analysis

Demographic and clinical data including age, sex, and vascular risk factors before AD, use of anticoagulants, coronary heart disease and peripheral arterial disease before AD, Marfan syndrome or bicuspid aortic valve were recorded and analyzed. Clinical follow-up was obtained during patient visits to the hospital, other hospital stays, or by telephone interview.

Computed Tomography Angiography (CTA) was performed with a variety of scanners, obtaining axial images with contiguous 1-mm or less thick sections from the supra-aortic vessels to the femoral arteries. All CTAs were performed with contrast material enhancement (100 mL to 120 mL of contrast). Acquisitions were performed at the arterial phase and also at a late phase (120 sec) to highlight low-flow endoleaks and FL patency. 3D reconstructions, with the Terarecon software (Yushima Bunkyo-ku, Tokyo, Japan) were used, for each control. Orthogonal aortic diameters including the maximum transaortic diameter, the true lumen and false lumen diameters at the corresponding plane were obtained at 4 levels, i.e. the aortic arch between the Left Common Carotid Artery (LCCA) and the LSA, the descending thoracic aorta at its maximum diameter, the thoraco-abdominal junction immediately upstream to the origin of the coeliac trunk and the subrenal aorta. For each intervention, a target level was identified among the four levels of analysis, defined as the most aneurysmal level.

FL patency was evaluated on the late phase acquisition. The status of the false lumen was evaluated according to a modified score of PARSA developed to summarize the status of the false lumen at the thoracic and abdominal levels [16]. The thoracic, abdominal and the overall false lumen score was obtained by the sum of each patency status at each level (patent=0, partially thrombosed =1, thrombosed =2) (i.e.: complete thrombosis of the thoracic and abdominal false lumen was evaluated as 4/4 score).

Aortic remodeling was assessed on the preprocedural and on the most recent Computed Tomography Angiography (CTA) follow-up for each patient and each intervention. The remodeling index was defined as the ratio between the true lumen diameter and the total transaortic diameter at the target level.

All patients had CTA in the postoperative course and also at 3, 6, and 12 months and once every year thereafter. All follow-up examinations were conducted by board-certified radiologists experienced in aortic dissections.

Statistical analysis

Qualitative variables are presented as sample size (n, percentage). Quantitative variables are presented as mean (± standard deviation) or median [interquartile range]. Univariate comparisons of qualitative variables were conducted using the Fisher exact test or the chi-squared test, and quantitative variables were compared using the Wilcoxon's rank-sum test or the Student's t-test. Statistical testing was conducted at an alpha level of 0.05 (two-tailed). Data were analyzed with the MedCalc Statistical Software version 17.6 (MedCalc Software bvba, Ostende, Belgium).

Results

Patients outcomes

At a median follow-up time of 60.7 months after dissection onset, Interquartile Range (IQR) [44.4-76.8], 59 ancillary endovascular procedures were performed in 35 patients.

Baseline demographic and clinical characteristics are presented (Table 1). At the end of the follow-up, thoracic and abdominal

Table 1: Patient's demographic and clinical characteristics.

n	35
Demographic characteristics	
Sex, male, n (%)	30 (85.7%)
Age (yrs) at dissection onset, mean (± SD)	63.4 (± 8.8)
Clinical characteristics	
Hypertension, n (%)	31 (88.6%)
Smoking, n (%)	17 (48.6%)
Diabetics, n (%)	2 (5.7%)
Hypercholesterolemia, n (%)	15 (42.9%)
Chronic kidney disease, n (%)	1 (2.9%)
Peripheral arterial disease, n (%)	0 (0%)
Stroke, n (%)	1 (2.9%)
Coronaropathie, n (%)	3 (8.6%)
Anévrisme de l'aorte abdominale, n (%)	4 (11.4%)
Bicuspid aortic valve, n (%)	1 (2.9%)
Marfan syndrome (genetic), n (%)	2 (5.7%)
Anticoagulant use, n (%)	11 (31.4%)
Aortic dissection characteristics	
Type A, n (%) Type B, n (%)	16 (45.7%) 19 (54.3%)
Acute (<14 days), n (%) Chronic (>14 days), n (%)	0 (0%) 35 (100%)
Previous proximal surgical repair: Ascending aortic replacement, n (%) Bentall, n (%)	18 (51.4%) 14 (40%) 4 (11.4%)
Number of visceral arteries arising from the false lumen (/5)*, median [IQR]	1 [0-2]
Median follow-up time since dissection onset, [IQR]	60.7 [44.4-76.8]
Median follow-up time since first ancillary procedure, [IQR]	35.4 [18.2-51.9]

*Considering coeliac trunk, superior mesenteric artery, left renal artery, right renal artery and inferior mesenteric artery

transaortic diameters were reduced or stable (<5 mm increase) in 85.7% of cases in 21 patients (60.0%) and complete thoraco-abdominal false lumen thrombosis in 9 patients (25.7%).

The mean total false lumen status score before the first ancillary procedure was 0.97 (± 0.90) *vs.* 2.54 (± 0.98) at the end of the follow-up, p<0.0001. The mean thoracic false lumen status score before the first ancillary procedure was 0.69 (± 0.54) *vs.* 1.59 (± 0.50) at the end of the follow-up, p<0.0001. The mean abdominal false lumen status score before the first ancillary procedure was 0.34 (± 0.54) *vs.* 1.09 (± 0.70) at the end of the follow-up, p<0.0001.

One patient presenting with a posterior circulation ischemic stroke complicating a chronic type A AD was successfully treated by sealing of a secondary entry tear in the proximal LSA with a covered stent. He was uneventful until the end of the follow-up at 2 years.

One patient with a left hemothorax complicating a chronic type A AD was treated in emergency, by combination of an aortic stent graft and a thoracic false lumen embolization procedure. He was thereafter treated one month later by a proximal stent graft extension due to the occurrence of a hemoptysis. He was then uneventful until the end of the follow-up, 60 months later.

One patient presenting with a pre-existing chronic type B aortic dissection with an 8-cm aneurysmal expansion of the thoracic aorta, died of a type A retrograde AD, 2 days after a complex two-step hybrid procedure including cervical debranching of the LCCA and the LSA with proximal extension of the stent-graft into landing zone 1.

Table 2: Overall procedural characteristics.

Sample size and temporal characteristics	
n	59
Number of interventions per patient, mean Type A AD Type B AD	1.7 1.75 1.63
Length of hospital stay (days), median [IQR]	5 [4-7]
Follow-up time (months), median [IQR]	10.6 [3.2-30.3]
Delay since dissection onset (months), median [IQR]	36.4 [15.3-57.1]
Procedural indication	
Aneurysmal expansion, n (%) Symptomatic, n (%) - Aortic rupture, n (%) - Malperfusion syndrome, n (%) - Recurrent pain, n (%)	55 (93.2%) 4 (6.8%) 2 (3.4%) 1 (1.7%) 1 (1.7%)
Main source of false lumen perfusion	
- Re-entry tear from a collateral artery, n (%) - Aortic secondary entry tear, n (%) - Stent-graft induced new entry (SINE), n (%) - Aortic secondary entry tear and collateral artery re-entry, n (%) - Type 2 endoleak, n (%) - Type 1 endoleak, n (%) - Intercostal arteries, n (%) - Collateral artery reentry and intercostal arteries, n (%) - Type 3 endoleak, n (%) - Type 2 endoleak and collateral artery re-entry, n (%)	18 14 12 5 3 2 2 1 1 1
Procedure type (some patients had combined procedures)	
Intervention on the true aortic lumen, n (%) Intervention on the true lumen of a collateral artery, n (%) Intervention on the false aortic lumen, n (%) Intervention on the false lumen of a collateral artery, n (%)	37 (62.7%) 26 (44.1%) 21 (35.6%) 10 (16.9%)

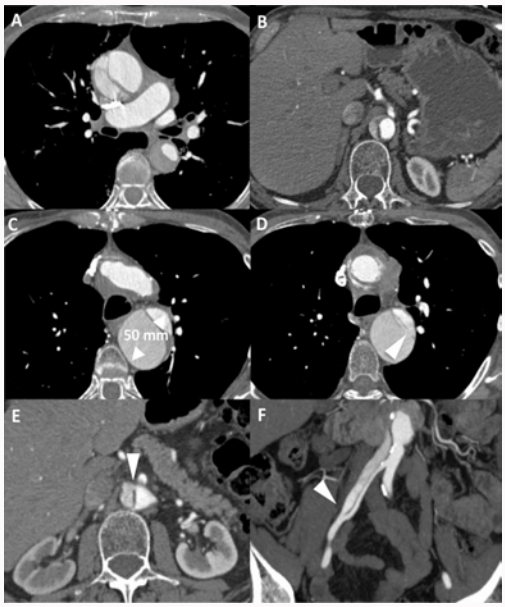

Figure 1: Patient presenting with an initial type A aortic dissection (Debakey type 1) (A and B).
Despite a correct surgical replacement of the ascending aorta, the 1-year CTA control is marked by a significant aneurysmal expansion of the descending aorta (C) due to: Secondary entry tears of the descending aorta (D, arrowhead), renal artery ostial desinsertion (E, arrowhead) and a re-entry located in the right common femoral artery (F, arrowhead).

Procedural outcomes

The median time between dissection onset and the ancillary

Table 3: Overall procedural outcomes.

		p
Total transaortic diameter		
Stability of all thoraco-abdominal diameters (decrease or increase <5 mm), n (%)	43 (72.9%)	
Target aortic level		
Total transaortic diameter stability (decrease or increase <5mm), n (%) Total transaortic diameter variation (mm), median [IQR] True lumen diameter variation (mm), median [IQR] False lumen diameter variation (mm), median [IQR] Remodeling index (%) Before intervention, mean (± SD) At last follow-up, mean (± SD)	55 (93.2%) -1 [(-6.8)-0] +6 [1.3–12.5] -6 [(-14.5)-(-3)] 39,3 (± 16.6) 56,9 (± 19.6)	<0.0001
False lumen thrombosis		
Total false lumen thrombosis score Before intervention, mean (± SD) At last follow-up, mean (± SD) Thoracic false lumen thrombosis score Before intervention, mean (± SD) At last follow-up, mean (± SD) Abdominal false lumen thrombosis score Before intervention, mean (± SD) At last follow-up, mean (± SD) False lumen thrombosis score at last follow-up > before intervention, n (%)	1.25 (± 0.9) 2.36 (± 1.0) 0.82 (± 0.51) 1.46 (± 0.54) 0.47 (± 0.60) 0.97 (± 0.67) 46 (80.0%)	<0.0001 <0.0001 <0.0001
Complications	4 (6.8%)	
In-hospital 30-days mortality, n (%)	1 (1.69%)	
Stroke or spinal cord ischemia	0 (0%)	
Vascular access false aneurysm	1 (1.69%)	
Iatrogenic asymptomatic collateral artery dissection	3 (5.1%)	

Figure 2: Successive ancillary endovascular procedures are conducted in order to close the secondary sources of false lumen perfusion. A thoracic aortic stent graft is deployed in landing zone 3, to close the secondary aortic entry tear (A and B). Selective catheterism of the right renal artery from the true lumen (C, arrowhead) with a 0.035" guidewire (C, arrow) is performed. The initial angiography confirms the false lumen perfusion through the renal artery desinsertion (C, star). A covered stent is deployed in the right renal artery (D, arrow) from the true aortic lumen. The completion angiography confirms the sealing of the entry tear (D).

procedure was 36.4 months, IQR [15.3-57.1]. The median procedural follow-up time was 10.6 months, IQR [3.2-30.3]. Procedural

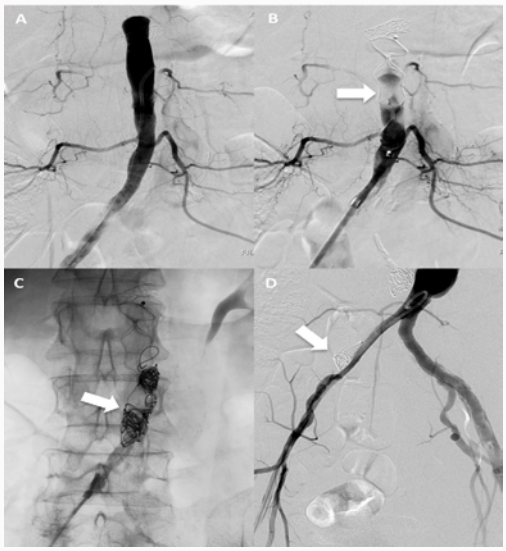

Figure 3: Selective catheterism of the false lumen is performed and the initial angiography confirms its patency (A). False lumen embolization with a type II 14 mm diameter Amplatzer plug (B, arrow) and multiple coils (C, arrow) is performed. The completion angiography confirms the sealing of the iliac re-entry tear (D, arrow).

Figure 4: CTA at the end of the follow-up, 44 months later demonstrates a complete thoraco-abdominal false lumen thrombosis and stability of the thoraco-abdominal diameters.

characteristics and procedural outcomes are presented (Table 2 and 3).

False aneurysm of a femoral artery access occurred in one procedure, following the insertion of a stent graft through a 24F sheath. It was successfully treated by percutaneous thrombin ultrasonography-guided embolization, without further complication.

Iatrogenic dissection of collateral arteries occurred in 3 procedures: Two common iliac arteries and one superior mesenteric

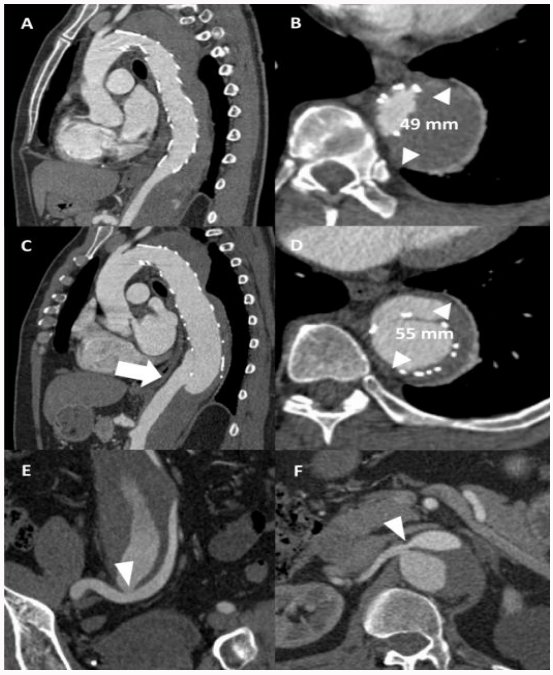

Figure 5: Patient presenting with a type B aortic dissection (Debakey type IIIb) treated by deployment of a thoracic aortic stent graft. Follow-up CTA at one year (A and B), shows a complete thoracic false lumen thrombosis. Nine months later (C-F), a new entry tear appears at the distal tip of the stent graft (C, arrow). Perforation of the dissection membrane by the stent-graft (stent-graft induced new entry) causes false lumen reperfusion and aneurysmal expansion of the descending aorta (D). Re-entry at the origin of the right common iliac artery (E, arrowhead) and desinsertion of the right renal artery (F, arrowhead) are also involved in the false lumen reperfusion.

artery and were successfully treated by covered and bare stents.

Discussion

The primary findings from our study are that complementary endovascular procedures are effective to promote aortic remodeling in chronic AD unfavorably evolving despite conventional treatments. As previously described, at the end of the follow-up, stabilization of thoracic and abdominal transaortic diameters occurred in 21 patients (60.0%), and 9 patients (25.7%) experienced complete thoraco-abdominal false lumen thrombosis. These results are in-line with the outcomes reported by Hofferberth et al. [11] who obtained stabilization of thoraco-abdominal aortic growth in 9/10 (90%) patients and complete false lumen thrombosis in 2/10 (20%) patients using ancillary false lumen embolization procedures. False lumen embolization seems to be a promising technique with a high technical success rate and an important efficiency on aortic remodeling [17]. Our strategy also demonstrated a median true lumen expansion of 6 mm [1.25 to 12.5] and a median false lumen shrinkage of -6 mm [(-14.5)-(-3)] at the target aortic level. These data are also consistent with those reported by Kim et al. [12] who demonstrated an effective expansion of the true lumen (before treatment 20.45 ± 5.33 mm versus after 25.12 ± 5.60 mm, $p<0.001$) and a shrinkage of the false lumen (before 22.23 ± 10.18 mm *vs.* after 17.56 ± 10.84 mm; $p<0.001$), in false lumen procedures for chronic Debakey type IIIB aneurysms. Likewise, Lombardi et al. [10] reported an effective stabilization of the transaortic diameter, a true lumen expansion and a false lumen shrinkage, performing TEVAR with a proximal stent graft and a distal bare metal stent extension [10].

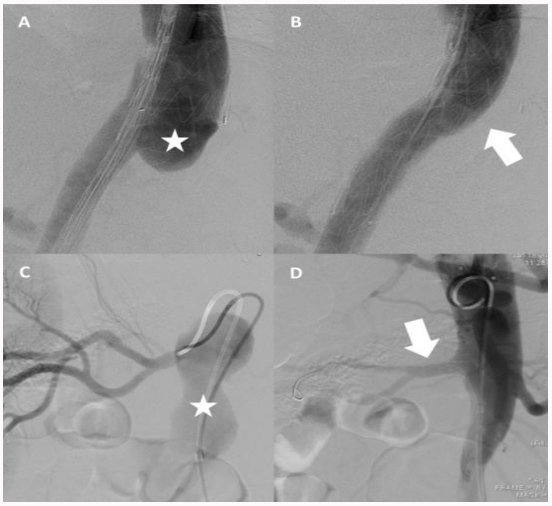

Figure 6: The initial aortography confirms the existence of a distal stent graft induced new entry (A, star). The deployment of a distal stent graft extension seals the SINE (B, arrow). Selective catheterism of the right renal artery from the true lumen is performed and the arteriography confirms the perfusion of the false lumen through the renal artery desinsertion (C, star). The deployment of a covered stent from the true aortic lumen to the right renal artery (D, arrow), seals the secondary entry tear.

Figure 7: The arteriography performed from the right true common iliac artery lumen confirms the perfusion of the false lumen through a secondary entry tear (A, star). The deployment of a covered stent in the right common and external iliac arteries seals this secondary entry tear (B, arrow).
Selective catheterism of the false abdominal aortic lumen shows the persistance of a false lumen patency, arising from lumbar arteries (C). False lumen embolization is performed with the deployment of a type II, 16 mm diameter Amplatzer plug.

The delay between the dissection onset and the ancillary procedure was markedly long in our population, reaching a median of 36.4 months [15.3 to 57.1]. In chronic aortic dissection, the dissection membrane progressively thickens and becomes stiff and immobile, with a supposed lower potential of remodeling [3,18]. Nevertheless, our results demonstrate that completion of the false lumen thrombosis, expansion of the true lumen and shrinkage of the false lumen are still achievable in those cases.

The only major complication of a complementary endovascular

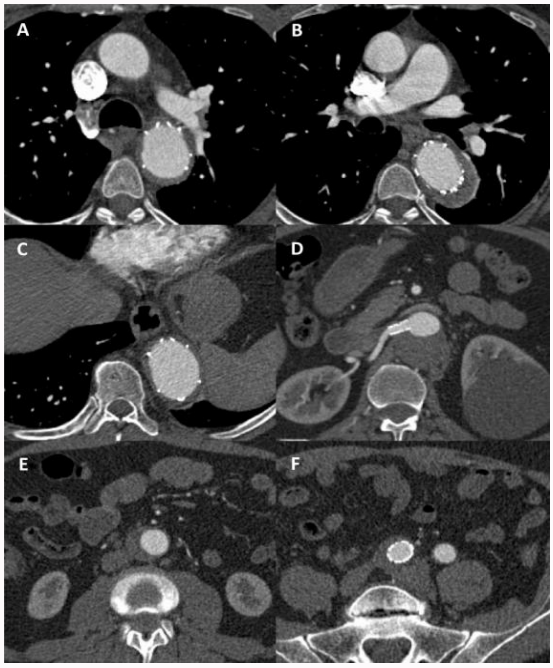

Figure 8: CTA at the end of the follow-up (A-F), 38 months later, demonstrates a complete thoraco-abdominal false lumen thrombosis and stability of the thoraco-abdominal diameters.

procedure was a retrograde type A aortic dissection following the proximal extension of a thoracic aortic stent graft, leading to early mortality. This patient presented with a pre-existing 8-cm aneurysmal expansion of the thoracic aorta, requiring an elective treatment. Retrograde aortic dissection is a known complication of thoracic endovascular aortic repair, occurring in 1.6% of cases, most often in the immediate postoperative period and carries a high mortality rate of 33.6% [19]. No excessive stent graft oversizing was implemented in this patient.

Conventional surgical and endovascular interventions on aortic dissections mainly aim to close the primary entry tear of the dissection membrane in order to redirect the blood flow towards the true aortic lumen and to depressurize the false lumen. Complete depressurization of the false lumen eventually leads to false lumen thrombosis. These characteristics called "aortic remodeling" have shown to be of clinical importance in numerous studies by resolving acute complications and preventing late aneurysmal expansion. Sueyoshi et al. [20] demonstrated that false lumen thrombosis prevents aortic aneurysmal expansion in chronic AD, with mean yearly aortic growth rates for completely closed false lumen, partially closed false lumen and patent false lumen of -0.2, 4 and 4.9 mm. Similarly, Tsai et al. reported that a partially closed false lumen is a predictor of mortality and Akutsu et al. have proved that patency of the false lumen is a risk factor for dissection-related death (hazard ratio 5.6) [21,22]. Tolenaar et al. [23] reported that expansion of the true lumen is associated with a decreased aortic growth rate. Finally, aortic remodeling have shown to be associated with a slower disease progression and a lower long-term aortic-related mortality in the INSTEAD-XL randomized controlled trial [4].

Predicting factors regarding false lumen thrombosis in patients with chronic TBAD have been outlined in different papers [24]. Thus, patients presented with TBAD and branch vessel involvement or a patent entry tear after TEVAR are less likely to develop FL

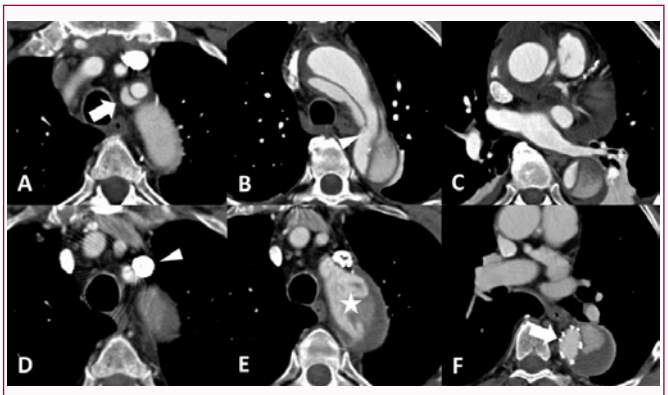

Figure 9: A patient presenting with an initial type A aortic dissection (Debakey type 1), was treated by surgical replacement of the ascending aorta. CTA follow-up at 6 months (A, B and C) shows persistent false lumen patency due to: A re-entry located in the origin of the left subclavian artery (A, arrow) and a secondary entry tear in the descending thoracic aorta (B, arrowhead). Despite the deployment of thoracic stent graft in landing zone 2 with occlusion of the origin of the left subclavian artery (D, arrowhead; F, arrow), a persistent false lumen patency lasts, arising from a type 1/2 endoleak causing growth of the descending thoracic aorta orthogonal diameters (C: 36 mm; F: 48 mm).

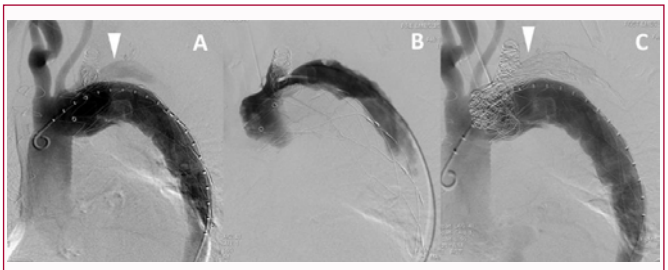

Figure 10: An ancillary endovascular procedure is performed in order to treat this endoleak. Selective catheterisms of the true lumen (A) and the false lumen (B) confirm that the false lumen is perfused by a type 1/2 endoleak (A, arrowhead and B). False lumen embolization of the aortic arch with multiple coils is achieved (C, arrowhead) and the completion angiography (C) shows an effective endoleak sealing.

thrombosis during follow-up. Recently, two trials also demonstrated that preoperative dissected thoracic branches fed by a false lumen are independently associated with total distal thoracic aortic enlargement after TEVAR in TBAD [7,25]. These patients may require a more intensive follow-up to prevent long-term complications.

Furthermore, TEVAR efficiency in chronic dissection is lower in term of aortic remodeling owing to the stiffness of the aortic flap and pressurization of the FL by retrograde flow through many distal entry tears [26,27].

In the literature, residual flow after TEVAR is probably under diagnosed in aortic dissection, and CTA modalities are not well described. In our study, we used a reproductive scan technique with an arterial and a late phase scan after contrast media injection. This technique demonstrated optimal detection of low-flow endoleaks and additional value in the assessment of the patency of the FL. Moreover, in the majority of papers on dissection, details concerning FL thrombosis are rarely described. For these reasons we used a new classification, which allows a clear definition of FL thrombosis, to compare each CT scan during the follow-up.

In case of aneurysmal expansion of the descending aorta, a more extensive procedure is needed to promote false lumen thrombosis by using different endovascular techniques. Moreover, precise analysis

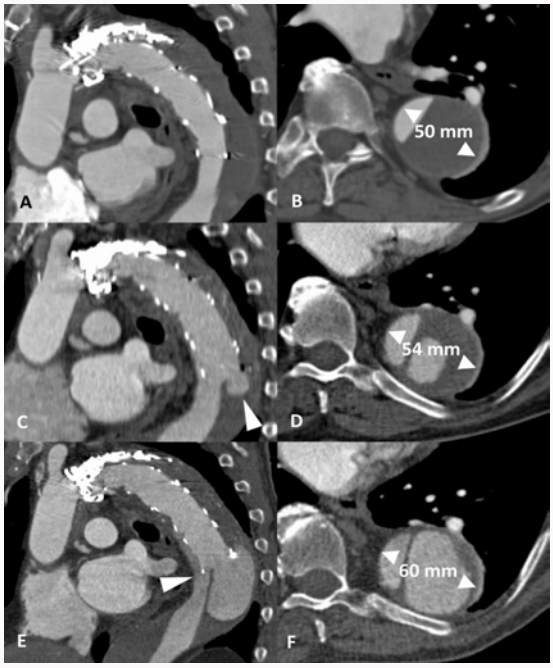

Figure 11: The first CTA follow-up at 4 months (A and B), shows a complete thoracic false lumen thrombosis with stability of the descending thoracic aorta orthogonal diameter.
Further CTA follow-up at 3 years (C and D) and 4 years (E and F) shows the appearance of a new entry tear located at the distal tip of the stent graft. Perforation of the dissection membrane by the stent-graft (SINE) causes false lumen reperfusion and aneurysmal expansion of the descending aorta.

Figure 12: The initial angiography through a pigtail catheter located in the true aortic lumen (A, arrow) shows the false lumen perfusion at the distal tip of the stent graft (A, star). The deployment of a distal stent graft extension successfully seals the SINE (B, arrow).
CTA at the end of the follow-up, 7 years later shows a complete thoraco-abdominal false lumen thrombosis and stability of the thoraco-abdominal aortic diameters (D: 52 mm).

of the anatomy of each particular case is mandatory to consider suitable therapeutic options.

Recently, some teams have started to treat patients with chronic dissections with fenestrated and branched stent grafts. This technique allows covering an even longer segment of the aorta occluding more entry points and reducing pressure and flow transmission into the false lumen. However, branched stent grafts, in complex anatomy, remain challenging, has a high rate of endoleak (more than 12% of patients presented a type I endoleak, and 50% a type II endoleak) and increase the risk of spinal cord ischemia (12.5%), probably owing to the length of aortic coverage [28,29].

One option is to occlude the false lumen flow by different techniques: the candy-plug, the Knickerbocker, and the embolization with combination of coils, plugs, onyx and glue.

Following the placement of a thoracic stent-graft into the true lumen to the level of the celiac artery, the Candy-plug technique use a back table modification of a stent-graft by adding a diameter-reducing suture to restrict the opening to a maximum diameter of ~10 mm still allowing for retraction of the dilator tip. Then, a 20-mm Amplatzer Vascular Plug II (AVP; St. Jude Medical, St. Paul, MN, USA) is deployed in the waist of the candy-wrapper shaped plug.

The concept of the Knickerbocker technique is based on a local forcefully dilation at the middle of a large diameter stent-graft placed in the true lumen, by using a compliant balloon [13]. The main advantage of the Knickerbocker technique is that it does not mandate the access of the false lumen, or the addition of more materials, but it is used essentially during the initial TEVAR placement for a subacute type B dissection and usually completed by a distal bare stent [15].

Another option is to promote FL thrombosis by sealing the entry tears or communications. Initially to reduce the flow and avoid distal migration of the materials, coils and plugs (Amplatzer Vascular Plug II, Abbott) are deployed in the FL with an adjacent liquid material to complete the embolization such as glue injection [30]. However, most of these materials are limited by the diameter of the false lumen (the largest commercially available devices are 24 mm in diameter) resulting in using more than one device or a lot of adjunctive embolization material in many cases.

Finally, occlusion of the reentries from the distal or proximal aorta, or the supraortic or visceral branches, could be a useful alternative.

We developed a staged aortic repair strategy with timely successive treatment of persistent flow within the thoracic false lumen causing complications. Proper planning and individualized selection of patients that are good candidates for false lumen thrombosis may be crucial. It is of note, that in the majority of cases, the false lumen thrombosis was achieved with intervention to the distal part of the dissection; however, in some cases a proximal or a mid-aortic embolization may be needed. This procedure could be undertaken either initially after TEVAR placement, when residual flow in the thoracic FL is observed or in chronic dissections cases after TEVAR or ascending thoracic aorta repair in which the false lumen remains patent increasing the risk of an adverse event. Moreover, in emergency cases of an acute rupture of false lumen, inducing the thrombosis of the false lumen may represent the only endovascular effective treatment to stop aortic bleeding. Our strategy demonstrates its efficiency to stabilize aortic diameters and promote false lumen thrombosis especially at the thoracic level, and to thwart the natural evolution of the disease towards late complications.

The learning curve related with these techniques should be acknowledged. Most of false lumen occlusion techniques require a high operator's technical skills level and a certain degree of practice to achieve a comfortable level of confidence for successful use. The development of referral centers may increase the experience on these techniques producing even better outcomes.

Our study has several strengths, including, to our knowledge, the larger study published so far, with the longer follow-up, a detailed evaluation of aortic remodeling and positive outcomes on disease progression. The results on aneurysmal size reduction were significant.

However, our study also has limitations due to its retrospective design on a procedure that is not commonly performed. We were not able to determine the effectiveness of each type of endovascular treatment because of frequently combined procedures. However, each chronic aortic dissection is a singular case according to the variable extension of the dissection on the aortic circumference and along the aortic and collaterals axis. This anatomic variability implies tailored therapeutic strategies, with the objective to provide an optimal aortic repair while maintaining blood flow in the vital branches. However, it is apparent that there is no randomized control trial in the literature. Studies published so far, included case reports or small case series presenting heterogeneity of data. Additionally, the techniques are not compared to each other in those studies. In most cases no detailed description of the previous endovascular intervention, complications and the re-intervention rate were available. Additionally, not all studies reported on false lumen status and diameter during follow up. Conversely, in our study an extensive et reproductive anatomic follow up was done with a strict definition of false lumen thrombosis.

Conclusion

Conventional treatments of aortic dissections are often insufficient to promote a complete aortic repair. The natural evolution of the disease and TEVAR-related new entries or endoleaks may induce recurrent pressurization of the false lumen leading to late complications. A close clinical and imaging follow-up is mandatory to detect disease progression. Further accurate analysis of each specific vascular anatomy allows to plan customized complementary endovascular procedures to seal false lumen sources of perfusion. This staged aortic repair strategy is safe and effective to promote aortic remodeling. Further studies are needed to better evaluate the indications and prognosis of these procedures.

Acknowledgement

The authors thank the CHU of Toulouse.

References

1. Hiratzka LF, Bakris GL, Beckman JA, Bersin RM, Carr VF, Casey DE, et al. 2010 ACCF/AHA/AATS/ACR/ASA/SCA/SCAI/SIR/STS/SVM guidelines for the diagnosis and management of patients with Thoracic Aortic Disease: A report of the American College of Cardiology Foundation/American Heart Association Task Force on Practice Guidelines, American Association for Thoracic Surgery, American College of Radiology, American Stroke Association, Society of Cardiovascular Anesthesiologists, Society for Cardiovascular Angiography and Interventions, Society of Interventional Radiology, Society of Thoracic Surgeons, and Society for Vascular Medicine. Circulation. 2010;121(13):e266-369.

2. Erbel R, Aboyans V, Boileau C, Bossone E, Bartolomeo RD, Eggebrecht H, et al. 2014 ESC Guidelines on The Diagnosis and Treatment of Aortic Diseases: Document Covering Acute and Chronic Aortic Diseases of The Thoracic and Abdominal Aorta of The Adult. The Task Force for the Diagnosis and Treatment of Aortic Diseases of the European Society of Cardiology (ESC). Eur Heart J. 2014;35(41):2873-926.

3. Alfson DB, Ham SW. Type B Aortic Dissections: Current Guidelines for Treatment. Cardiol Clin. août 2017;35(3):387-410.

4. Nienaber CA, Kische S, Rousseau H, Eggebrecht H, Rehders TC, Kundt G, et al. Endovascular repair of type b aortic dissection: Long-term results of the randomized investigation of stent grafts in aortic dissection trial. Circ Cardiovasc Interv. 2013;6(4):407-16.

5. Kusagawa H, Shimono T, Ishida M, Suzuki T, Yasuda F, Yuasa U, et al. Changes in False Lumen After Transluminal Stent-Graft Placement in Aortic Dissections: Six Years' Experience. Circulation. 2005;111(22):2951-7.

6. Li D, Ye L, He Y, Cao X, Liu J, Zhong W, et al. False Lumen Status in Patients with Acute Aortic Dissection: A Systematic Review and Meta-Analysis. J Am Heart Assoc. 2016;5(5).

7. Kamman AV, Brunkwall J, Verhoeven EL, Heijmen RH, Trimarchi S; ADSORB trialists. Predictors of Aortic Growth in Uncomplicated Type B Aortic Dissection from the Acute Dissection Stent Grafting or Best Medical Treatment (Adsorb) Database. J Vasc Surg. avr 2017;65(4):964-71.e3.

8. Nienaber CA, Rousseau H, Eggebrecht H, Kische S, Fattori R, Rehders TC, et al. Randomized Comparison of Strategies for Type B Aortic Dissection: The Investigation of Stent Grafts in Aortic Dissection (Instead) Trial. Circulation. 2009;120(25):2519-28.

9. Tanaka A, Sakakibara M, Ishii H, Hayashida R, Jinno Y, Okumura S, et al. Influence of The False Lumen Status on Clinical Outcomes in Patients with Acute Type B Aortic Dissection. J Vasc Surg. 2014;59(2):321-6.

10. Lombardi JV, Cambria RP, Nienaber CA, Chiesa R, Mossop P, Haulon S, et al. Aortic remodeling after endovascular treatment of complicated type B aortic dissection with the use of a composite device design. J Vasc Surg. 2014;59(6):1544-54.

11. Hofferberth SC, Nixon IK, Mossop PJ. Aortic False Lumen Thrombosis Induction by Embolotherapy (After) Following Endovascular Repair of Aortic Dissection. J Endovasc Ther 2012;19(4):538-45.

12. Kim TH, Song SW, Lee KH, Baek MY, Yoo KJ. Effects of False Lumen Procedures on Aorta Remodeling of Chronic DeBakey IIIb Aneurysm. Ann Thorac Surg. 2016;102(6):1941-7.

13. Kölbel T, Carpenter SW, Lohrenz C, Tsilimparis N, Larena-Avellaneda A, Debus ES. Addressing Persistent False Lumen Flow in Chronic Aortic Dissection: The Knickerbocker Technique. J Endovasc Ther Off J Int Soc Endovasc Spec. 2014;21(1):117-22.

14. Kölbel T, Lohrenz C, Kieback A, Diener H, Debus ES, Larena-Avellaneda A. Distal false lumen occlusion in aortic dissection with a homemade extra-large vascular plug: The candy-plug technique. J endovasc ther off j int soc endovasc spec. 2013;20(4):484-9.

15. Faure EM, El Batti S, Abou Rjeili M, Julia P, Alsac J-M. Mid-Term Outcomes of Stent Assisted Balloon Induced Intimal Disruption and Relamination in Aortic Dissection Repair (Stabilise) in Acute Type B Aortic Dissection. Eur J Vasc Endovasc Surg. 2018;56(2):209-15.

16. Parsa CJ, Williams JB, Bhattacharya SD, Wolfe WG, Daneshmand MA, McCann RL, et al. Midterm results with thoracic endovascular aortic repair for chronic type B aortic dissection with associated aneurysm. J Thorac Cardiovasc Surg. 2011;141(2):322-7.

17. Pellenc Q, Roussel A, De Blic R, Girault A, Cerceau P, Ben Abdallah I, et al. False lumen embolization in chronic aortic dissection promotes thoracic aortic remodeling at midterm follow-up. J Vasc Surg. 2019;70(3):710-17.

18. Criado FJ. Aortic dissection: A 250-year perspective. Tex Heart Inst J. 2011;38(6):694-700.

19. Canaud L, Ozdemir BA, Patterson BO, Holt PJE, Loftus IM, Thompson

Mm. Retrograde Aortic Dissection after Thoracic Endovascular Aortic Repair. Ann Surg. 2014;260(2):389-95.

20. Sueyoshi E, Sakamoto I, Uetani M. Growth Rate of Affected Aorta in Patients with Type B Partially Closed Aortic Dissection. Ann thorac surg. 2009;88(4):1251-7.

21. Tsai TT, Evangelista A, Nienaber CA, Myrmel T, Meinhardt G, Cooper JV, et al. Partial Thrombosis of the False Lumen in Patients with Acute Type B Aortic Dissection. N Engl J Med. 2007;357(4):349-59.

22. Akutsu K, Nejima J, Kiuchi K, Sasaki K, Ochi M, Tanaka K, et al. Effects of the patent false lumen on the long-term outcome of type B acute aortic dissection. Eur J Cardio-thorac Surg. 2004;26(2):3591-66.

23. Tolenaar JL, van Keulen JW, Jonker FHW, van Herwaarden JA, Verhagen HJ, Moll FL, et al. Morphologic Predictors of Aortic Dilatation in Type B Aortic Dissection. J Vasc Surg. 2013;58(5):1220-5.

24. Schwartz SI, Durham C, Clouse WD, Patel VI, Lancaster RT, Cambria RP, et al. Predictors of Late Aortic Intervention in Patients with Medically Treated Type B Aortic Dissection. J Vasc Surg. 2018;67(1):78-84.

25. Ge YY, Guo W, Cheshire N, Liu XP, Jia X, Xiong J, et al. Preoperative thoracic false lumen branches relate to aortic remodeling after thoracic endovascular aortic repair for DeBakey IIIb aortic dissection. J Vasc Surg. 2017;65(3):659-68.e2.

26. Conway AM, Qato K, Mondry LR, Stoffels GJ, Giangola G, Carroccio A. Outcomes of Thoracic Endovascular Aortic Repair for Chronic Aortic Dissections. J vasc surg. 2018;67(5):1345-52.

27. Scali ST, Feezor RJ, Chang CK, Stone DH, Hess PJ, Martin TD, et al. Efficacy of Thoracic Endovascular Stent Repair for Chronic Type B Aortic Dissection with Aneurysmal Degeneration. J Vasc Surg. 2013;58(1):10-17.

28. Spear R, Hertault A, Van Calster K, Settembre N, Delloye M, Azzaoui R, et al. Complex Endovascular Repair of Postdissection Arch and Thoracoabdominal Aneurysms. J Vasc Surg. 2018;67(3):685-93.

29. Bisdas T, Panuccio G, Sugimoto M, Torsello G, Austermann M. Risk Factors for Spinal Cord Ischemia after Endovascular Repair of Thoracoabdominal Aortic Aneurysms. J Vasc Surg. 2015;61(6):1408-16.

30. Yuan X, Mitsis A, Semple T, Castro Verdes M, Cambronero-Cortinas E, Tang Y, et al. False Lumen Intervention to Promote Remodeling and Thrombosis-the Flirt Concept in Aortic Dissection. Catheter Cardiovasc Interv. 2018;92(4):732-40.