Clinics in Surgery

Research Article
Published: 22 Dec, 2016

Changes in Blood Coagulation and Fibrinolysis Markers Before and After Spinal Surgery in Adolescent and Older Patients

Hideaki Watanabe[1], Hirokazu Inoue[2], Akira Murayama[2], Shinya Hayasaka[3], Ichiro Kikkawa[1] and Katsushi Takeshita[2]*

[1]Department of Pediatric Orthopedic Surgery, Jichi Children's Medical Center, Japan

[2]Department of Orthopedic Surgery, Jichi Medical University, Japan

[3]Department of Human Life Sciences, Tokyo City University, Japan

Abstract

Aim: To investigate changes in blood coagulation and fibrinolysis markers before and after spinal surgery in adolescent and older patients and to explore possible reasons for the development of postoperative venous thromboembolism (VTE).

Methods: This retrospective two-center study enrolled 57 low-risk patients who underwent spinal surgery at either our children's institution or our public hospital between October 2012 and April 2015. Altogether, 27 adolescent idiopathic scoliosis (AIS) patients (3 boys, 24 girls; mean age 15 years, range 11–19 years) underwent instrumentation for posterior fusion. Also, 30 lumbar spinal canal stenosis (LSCS) patients (16 men, 15 women; mean age 71 years, range 52–88 years) underwent laminectomy for posterior decompression. Plasma levels of soluble fibrin monomer complex (SFMC), D-dimer, and plasminogen activator inhibitor type 1 (PAI-1) were measured 1 day preoperatively and on postoperative days (PODs) 1, 3, and 7.

Results: No patients in this study developed symptomatic or asymptomatic VTE postoperatively. The SFMC level showed significant increases on PODs 1 and 3 in the AIS patients and on POD 1 in the LSCS patients. The D-dimer level showed significant increases on PODs 1, 3, and 7 in both groups. The PAI-1 levels showed significant increases on POD 7 in the AIS patients and on PODs 1, 3, and 7 in the LSCS patients.

Conclusion: The significantly higher postoperative PAI-1 levels in older patients could be associated with the development and progression of symptomatic VTE.

Keywords: Venous thromboembolism; Adolescent idiopathic scoliosis; Spinal surgery; Blood coagulation-fibrinolysis marker; D-dimer; Soluble fibrin monomer complex; Plasminogen activator inhibitor type 1

OPEN ACCESS

Correspondence:
Hideaki Watanabe, Department of Pediatric Orthopedic Surgery, Jichi Children's Medical Center, 3311-1 Yakushiji, Shimotsuke, Tochigi 329-0498, Japan, Tel: +81-285-58-7374; Fax: +81-285-44-1301; E-mail: watahide1968@jichi.ac.jp

Received Date: *23 Aug 2016*
Accepted Date*: 15 Dec 2016*
Published Date*: 22 Dec 2016*

Citation:
Watanabe H, Inoue H, Murayama A, Hayasaka S, Kikkawa I, Takeshita K. Changes in Blood Coagulation and Fibrinolysis Markers Before and After Spinal Surgery in Adolescent and Older Patients. Clin Surg. 2016; 1: 1255.

Introduction

Venous thromboembolism (VTE) is a common complication after spinal surgery in adults. It is important to identify postoperative VTE, particularly fatal pulmonary embolism (PE) and symptomatic PE, which can be life threatening. Antithrombotic drugs are administered to reduce the postoperative risk of VTE, but these medications cannot be administered during or after spinal surgery because of the risk of postoperative paralysis resulting from hematoma. The overall reported incidence of symptomatic deep vein thrombosis (DVT) associated with spinal surgery ranges from 0.3% to 31.0% [1], and that of symptomatic VTE associated with spinal fusion surgery is 0.4% [2]. In Japan, the reported incidence of symptomatic PE is 0.6% [3] and that of asymptomatic VTE is 19% (DVT 5%, PE 18%) [3].

The incidence of VTE after spinal surgery in adolescent patients [4,5], as in younger children [6,7], is rare compared with the incidence among older patients. It is not known how blood coagulation and fibrinolysis, which are related to VTE, change after spinal surgery in adolescent patients, whereas a few studies have investigated those changes in older patients. It is possible that VTE could be prevented if differences in the changes in blood coagulation and fibrinolysis markers after spinal surgery in adolescent and older patients without VTE could be clarified. The purpose

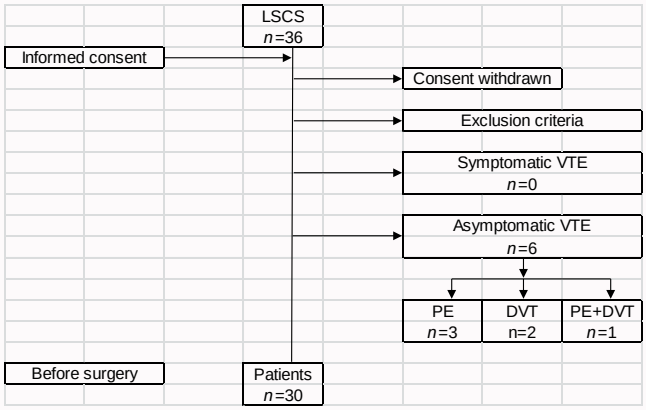

Figure 1: Flowchart of the 36 patients before surgery in the LSCS group. DVT: Deep Vein Thrombosis; LSCS: Lumbar Spinal Canal Stenosis; *n*: Number of Patients; PE: Pulmonary Embolism; VTE: Venous Thromboembolism

of this study was to investigate the changes in blood coagulation and fibrinolysis markers before and after spinal surgery in adolescent and older patients and to attempt to determine the reasons for VTE development after spinal surgery.

Materials and Methods

The ethics review board of our university approved the study protocol. This retrospective two-center study enrolled patients who underwent spinal surgery at our children's institution or public hospital between October 2012 and April 2015. Patients with a past history of symptomatic VTE, cerebral hemorrhage, cerebral infarction, cardiac infarction, or allergy to contrast medium were excluded from the study. Patients with liver disease, renal disease, or congenital clotting factor deficiencies and those undergoing antithrombotic therapy or hemodialysis were also excluded, as were older patients with asymptomatic VTE diagnosed with preoperative and postoperative contrast-enhanced 16-row multidetector row computed tomography (MDCT) (Figure 1). Older patients with hypertension, diabetes mellitus, or rheumatoid arthritis were included in this study. We did not investigate preoperative and postoperative VTE with MDCT in adolescent patients because the incidence of VTE before and after spinal surgery in this age group is rare, and there is a problem with the exposure dose for young patients.

We enrolled 57 consecutive low-risk patients who underwent spinal surgery. A total of 27 patients (3 boys, 24 girls; mean age 15 years, range 11–19 years) with adolescent idiopathic scoliosis (AIS) underwent instrumentation for posterior fusion. A group of 30 older patients (15 men, 15 women; mean age 71 years, range 52–88 years) with lumbar spinal canal stenosis (LSCS) underwent laminectomy for posterior decompression (Figure 1). There were significant differences between the two groups with regard to age, sex, volume of intraoperative hemorrhage, and operation time (Table 1).

Instrumentation for posterior fusion and laminectomy for posterior decompression were performed under general anesthesia, with all patients in a prone position. During and after surgery, both groups of patients wore elastic stockings and used an intermittent pneumatic compression device until the initiation of walking training, in accordance with the Japanese Guideline for Prevention of Venous Thromboembolism [8]. No postoperative prophylactic antithrombotic therapy was administered in either group. If a patient

Table 1: Patient Demographics.

	AIS	LSCS	P
Mean age (range)	15 yr (11-19)	71 yr (52-88)	0.01*
Sex (Male: Female)	3:24	16:15)	0.01**
Mean intraoperative hemorrhage (range)	653ml (0-1285)	145ml (20-460)	0.01*
Mean operation time (range)	430 min (238-799)	100 min (37-203)	0.01*

AIS: Adolescent Idiopathic Scoliosis; LSCS: Lumbar Spinal Canal Stenosis; *Unpaired t-test; **Fisher's exact test

developed symptomatic VTE, the study was discontinued and aggressive antithrombotic therapy initiated.

Blood coagulation and fibrinolysis markers

Blood samples were obtained to measure the plasma levels of soluble fibrin monomer complex (SFMC), D-dimer, and plasminogen activator inhibitor type 1 (PAI-1) 1 day preoperatively and on postoperative days (PODs) 1, 3, and 7. Citrated plasma samples were stored at −80°C until analysis. Plasma SFMC and D-dimer levels were measured with latex immunoagglutination assays (Mitsubishi Chemical Medience Corporation, Tokyo, Japan) using the monoclonal antibodies IF-43 and JIF-23, respectively [9,10]. Plasma PAI-1 levels were measured with a latex photometric immunoassay (Mitsubishi Chemical Medience Corporation) using the polyclonal antibody F(ab′) fragment [11].

Statistical analysis

Statistical analyses were performed with IBM SPSS for Windows, version 20.0 (SPSS, Chicago, IL, USA). If the SFMC, D-dimer, and PAI-1 levels did not fit a normal distribution, they were analyzed using the Shapiro–Wilk test. The SFMC, D-dimer, and PAI-1 levels 1 day preoperativelywere compared with thoseon PODs 1, 3, and 7 using the Friedman test. If a significant difference was noted, the data were compared using the Wilcoxon signed rank test and corrected with Bonferroni's inequality. Patients' sex in the AIS and LSCS groups was compared with Fisher's exact test. Age, volume of intraoperative hemorrhage, and operation time were compared with an unpaired t-test. The level of statistical significance was set at $P< 0.05$ for all tests.

Results

No patients in either the AIS or LSCS group developed symptomatic VTE after spinal surgery. Also, MDCT showed that none of the patients in the LSCS group developed asymptomatic VTE after spinal surgery.

Changes in blood coagulation and fibrinolysis markers after AIS surgery

The SFMC level was significantly higher on PODs1 (median 10.0 μg/ml, P = 0.01) and 3 (median 10.0 μg/ml, P= 0.01) than preoperatively (median 3.0 μg/ml) (Figure 2). The D-dimer level was significantly higher on PODs 1 (median 1.8 μg/ml, P =0.01), 3 (median 2.8 μg/ml, P=0.01), and 7 (median 5.5 μg/ml, P=0.01) than preoperatively (median 0.3 ng/ml) (Figure 2). The PAI-1 level was significantly higher on POD 7 (median 16.0 ng/ml, P=0.01) than preoperatively (median 14.0 ng/ml) (Figure 2).

Changes in blood coagulation and fibrinolysis markersafter LSCS surgery

The SFMC level was significantly higher on POD 1 (median 3.6 μg/ml, P=0.01) than preoperatively (median 2.9 μg/ml) (Figure 3). The D-dimer level was significantly higher on PODs 1 (median 3.5

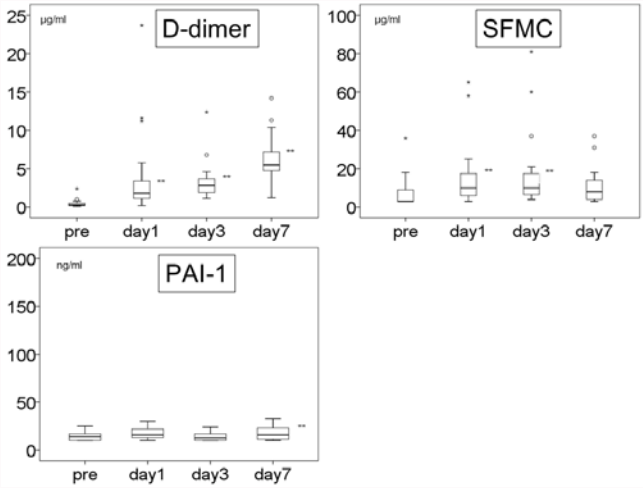

Figure 2: Changes in soluble fibrin monomer complex (SFMC), D-dimer, and plasminogen activator inhibitor type 1 (PAI-1) levels before and after surgery in the AIS group. Open circles: outliers. *External value. Pre, preoperatively. **P< 0.05, versus the preoperative level according to the Wilcox on signed rank test with correction by Bonferroni's inequality.

μg/ml, P=0.01), 3 (median 1.9 μg/ml, P=0.01), and 7 (median 4.8 μg/ml, P=0.01) than preoperatively (median 0.5 μg/ml) (Figure 3). The PAI-1 level was significantly higher on PODs 1 (median 25.0 ng/ml, P=0.01), 3 (median 25.0 ng/ml, P=0.01), and 7 (median 30.0 ng/ml, P=0.01) than preoperatively (median 17.0 ng/ml) (Figure 3).

Discussion

In daily clinical practice, orthopedic surgeons are aware that the incidence of VTE after orthopedic surgery in young patients is rare compared with the incidence in older patients. There are few articles to prove this difference, however, because young and older patients do not undergo the same surgery. For this reason, we selected the most popular spinal surgery performed in these two groups- although there was the difference in the severity of the surgery between the groups- and compared three markers in each before and after surgery.

The significant elevations in SFMC and D-dimer levels beginning on POD 1 indicated that changes in coagulation and fibrinolysis developed at an early stage after spinal surgery in patients treated for AIS and for LSCS. After this initial increase, coagulation was inhibited and fibrinolysis remained activated. After that, fibrinolysis was inhibited on PODs 3–7, as indicated by the significantly elevated PAI-1 levels on those days in both the AIS and LSCS groups.

Few studies have investigated changes in blood coagulation and fibrinolysis markers before and after spinal surgery, although a few have compared these markers in patients with and without VTE- but only after spinal surgery. Hamidi and Riazi [12] reported that D-dimer levels were significantly elevated on PODs 1,3, and 10 in spinal surgery patients with VTE compared with those without VTE. Yoshioka et al. [13] reported that SFMC levels were significantly elevated on POD 1 and that D-dimer levels were significantly elevated on POD 7 in spinal surgery patients with VTE compared with those without VTE. Based on these data from the patients without VTE, we speculated that SFMC levels on POD 1 and D-dimer levels on PODs 1,3, and 7 would be elevated, although the elevation was not statistically significant. And based on our results and those from past articles, we think it is possible that the elevation in the D-dimer levels on PODs 1,3, and 7 and the elevated SFMC on PODs 1and 3 represent normal coagulation–fibrinolysis responses after spinal surgery. Also, based on the data from the past articles, changes in the D-dimer and SFMC levels after spinal surgery might be greater in patients with VTE than in those without VTE.

The PAI-1 level on PODs 1–3 was significantly higher in our patients treated for LSCS than in those treated for AIS. These findings indicate that older patients had more coagulative changes inhibiting fibrinolysis than did the adolescent patients because it is more difficult for older patients to form a thrombus. The significantly higher level of postoperative PAI-1 in older patients could be associated with the development and progression of symptomatic VTE. Few studies have investigated PAI-1 levels in patients undergoing spinal surgery. Yukizawa et al. [14] reported that PAI-1 levels were significantly elevated on PODs 1 and 7in patients with VTE following total hip arthroplasty. Watanabe et al. [15] reported that the PAI-1 level 90s after release of a pneumatic tourniquet during total knee arthroplasty was significantly elevated in patients with VTE. PAI-1 inhibits plasminogen activator and leads to production of fibrin or thrombus [16]. We believe that continuously inactivated fibrinolysis due to PAI-1 may lead to VTE in older patients after spinal surgery.

A limitation of this study is that we did not investigate postoperative VTE using modalities such as MDCT or ultrasonography in the adolescent patients because the incidence of VTE after spinal surgery is rare in this age group [4,5]. Another limitation is that the sample size was relatively small.

Conclusion

We investigated changes in blood coagulation and fibrinolysis markers before and after spinal surgery in adolescent and older patients. The PAI-1 level was significantly elevated on PODs 1–3 after spinal surgery in patients treated for LSCS compared with that of patients treated for AIS. The significantly higher level of postoperative PAI-1 in older patients could be associated with the development and progression of symptomatic VTE.

References

1. Glotzbecker MP, Bono CM, Wood KB, Harris MB. Thromboembolic disease in spinal surgery: a systematic review. Spine (Phila Pa 1976). 2009; 34: 291-303.

2. Gephart MG, Zygourakis CC, Arrigo RT, Kalanithi PS, Lad SP, Boakye M. Venous thromboembolism after thoracic/thoracolumbar spinal fusion. World Neurosurg. 2012; 78: 545-552.

3. Takahashi H, Yokoyama Y, Iida Y, Terashima F, Hasegawa K, Saito T, et al. Incidence of venous thromboembolism after spine surgery. J Othop Sci. 2012; 17: 114-117.

4. Kaabachi O, Alkaissi A, Koubaa W, Aloui N, ToumiNel H. Screening for deep venous thrombosis after idiopathic scoliosis surgery in children: a pilot study. Pediatr Anesth. 2010; 20: 144-149.

5. Meng XL, Zhao H, Su QJ, Hai Y. Acute pulmonary embolism following adolescent idiopathic scoliosis correction surgery: case report and review of literature. J Int Med Res. 2013; 41: 1759-1767.

6. Jain A, Karas DJ, Skolasky RL, Sponseller PD. Thromboembolic complications in children after spinal fusion surgery. Spine. 2014; 39: 1325-1329.

7. Sabharwal S, Zhao C, Passanante M. Venous thromboembolism in children: details of 46 cases based on a follow-up survey of POSNA members. J Pediatr Orthop. 2013; 33: 768-774.

8. Editorial Committee on Japanese Guideline for Prevention of Venous

Thromboembolism: Digest. 2nd ed. Tokyo: Medical Front International Limited. 2004: 15-16.

9. Soe G, Kohno I, Inuzuka K, Itoh Y, Matsuda M. A monoclonal antibody that recognizes a neo-antigen exposed in the E domain of fibrin monomer complexed with fibrinogen or its derivatives: its application to the measurement of soluble fibrin in plasma. Blood.1996; 88: 2109-2117.

10. Matsuda M, Terukina S, Yamazumi K, Maekawa H, Soe G. A monoclonal antibody that recognizes the NH_2-terminal conformation of fragment D. p.43–48. In: Fibrinogen 4, Current Basic and Clinical Aspects: Proceedings of the International Fibrinogen Workshop, Kyoto, Japan. 27–28 August 1989. Amsterdam: ExcerptaMedica. 1990; 43-48.

11. Ono T, Sogabe M, Ogura M, Furusaki F. Automated latex photometric immunoassay for total plasminogen activator inhibitor-1 in plasma. Clin Chem. 2003; 49: 987-989.

12. Hamidi S, Riazi M. Cutoff values of plasma D-dimer level in patients with diagnosis of the venous thromboembolism after elective spinal surgery. Asian Spine J. 2015; 9: 232-238.

13. Yoshioka K, Kitajima I, Kabata T, Tani M, Kawahara N, Murakami H, et al. Venous thromboembolism after spine surgery: changes of the fibrin monomer complex and D-dimer level during the perioperative period. J Neurosurg Spine. 2010; 13: 594-599.

14. Yukizawa Y, Inaba Y, Watanabe S, Yajima S, Kobayashi N, Ishida T, et al. Association between venous thromboembolism and plasma levels of both soluble fibrin and plasminogen-activator inhibitor in 170 patients undergoing total hip arthroplasty. Acta Orthopaedica. 2012; 83: 12-21.

15. Watanabe H, Kikkawa I, Madoiwa S, Sekiya H, Hayasaka S, Sakata Y. Changes in blood coagulation-fibrinolysis markers by pneumatic tourniquet during total knee joint replacement with thromboembolism. J Arthroplasty. 2014; 29: 569-573.

16. Watanabe H, Inoue H, Murayama A, Hayasaka S, Takeshita K, Kikkawa I. Prediction of venous thromboembolism after total knee arthroplasty using blood coagulation-fibrinolysis markers: A systematic review. Int J Orthopaed. 2015; 23: 280-283.