



## Cerebral Infarction Revealing a Cardiac Hydatid Cyst

Rabiou S<sup>1\*</sup>, Moussa TD<sup>2</sup>, Obenda NS<sup>2</sup>, Sanoussi S<sup>3</sup> and El Kouach M<sup>4</sup>

<sup>1</sup>Department of Thoracic Surgery, Centre Hospitalier Universitaire Hassan II, Morocco

<sup>2</sup>Department of Medical Neurology, Centre Hospitalier Universitaire Hassan II, Morocco

<sup>3</sup>Department of Neurosurgery, HNN, Niamey, Niger

<sup>4</sup>Department of Cardiac surgery, Centre Hospitalier Universitaire Hassan II, Morocco

### Abstract

The author's report the case of an ischemic stroke complicating cardiac hydatid cyst in a young patient. This is a rare clinical situation of accidental discovery in the workup of an ischemic stroke. The systematic cardiovascular examination with a cardiac ultrasound allowed us to suspect this diagnosis given the context of hydatid endemic. The support consisted of surgical excision of hydatid cyst under cardiopulmonary bypass. The postoperative course was marked by the occurring of an array of respiratory distress at Day 5 post surgery.

**Keyword:** Cerebral infarction; Cardiac ultrasonography; Hydatidosis

### Introduction

The lung is the most frequent location of hydatid cysts [1]. Cardiac and vascular hydatid cysts are rare, and the primary location in the wall of the left cardiac ventricle is exceptional. Cerebral infarction complicating cardiac hydatid cyst in a young patient is a rare clinical situation but possible. In the etiological investigation for cerebral infarction, the possibility of a hydatid cyst should be suspected. A clinical examination and cardiovascular exploration with at least un-echocardiography should be systematic especially in a hydatid endemic area.

### Case Presentation

A 31 year old man was hospitalized for neurological deficit of the left half of the body of acute onset that had occurred nine days earlier. The examination on admission noted a left sided hemiparesis and hemihypoesthesia with facial involvement associated with a homonymous hemianopia. Brain scan showed bilateral brain hypodensities. The magnetic resonance imaging (MRI) revealed recent bilateral superficial MCA infarction and a right posterior cerebral infarction (Figure 1). In the etiological investigation for cerebral infarction in a young patient, echocardiography was performed and had uncovered a large poly-cystic mass in the depth of the anterolateral wall of the left ventricle with mobile intraventricular fragment. Ultrasound of the supra-aortic trunks was normal. Chest

### OPEN ACCESS

#### \*Correspondence:

Sani Rabiou, Department of Thoracic Surgery, Centre Hospitalier Universitaire Hassan II-Fez, Morocco, Tel: 212-680-772-220;

E-mail: rabiouani2@icloud.com

Received Date: 18 Jul 2016

Accepted Date: 10 Aug 2016

Published Date: 02 Sep 2016

#### Citation:

Rabiou S, Moussa TD, Obenda NS, Sanoussi S, El Kouach M. Cerebral Infarction Revealing a Cardiac Hydatid Cyst. Clin Surg. 2016; 1: 1097.

Copyright © 2016 Rabiou S. This is an open access article distributed under the Creative Commons Attribution License, which permits unrestricted use, distribution, and reproduction in any medium, provided the original work is properly cited.

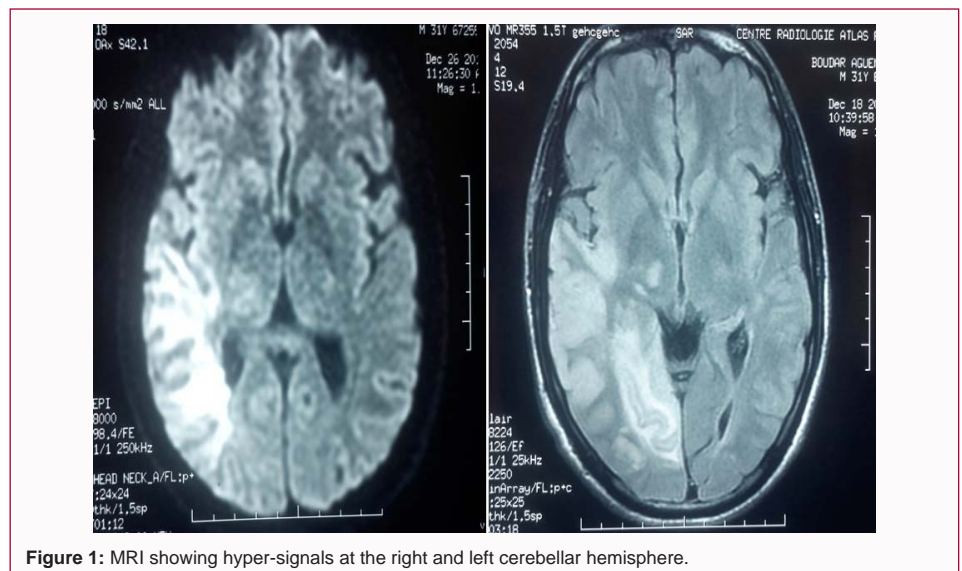
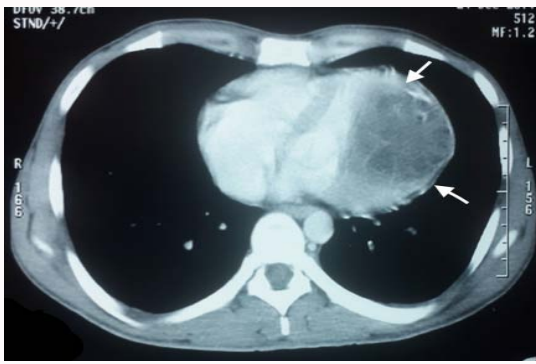

Figure 1: MRI showing hyper-signals at the right and left cerebellar hemisphere.



**Figure 2:** Chest CT scan showing a massive cardiac hydatid cyst of the left ventricle.

computed tomography showed a myocardial multi-vesicular cystic mass with calcifications (Figure 2). Surgical exploration with cardiopulmonary bypass had uncovered a hydatid cyst ruptured into the left ventricle with the presence of free vesicles. The postoperative course was marked by the appearance of an array of severe respiratory distress that led to patient's death on 5th postoperative day despite resuscitative measures in the intensive care unit.

## Discussion

Hydatid cyst of the heart and blood vessels is rare, and carries a very poor prognosis. They represent 0.2 to 3% of all hydatid disease localisations [2,3]. This scarcity is explained partly by the need to cross the liver and the pulmonary bed by the scolices before reaching the coronary circulation and partly by the natural resistance to the

establishment of viable cysts offered by cardiac contractions [4]. The right heart cavities are less frequently affected than left heart cavities because of the thickness of their wall and their less vascularized nature. The multi-vesicular nature of the cyst and the discovery of free vesicles in the heart chambers, in our patient suggest that the occurrence of cerebral infarction is secondary to migration of a hydatid embolus in the systemic circulation. The obstruction in the small sized cerebral vessels would be the cause of ischemia by interruption of blood flow [5]. Surgical excision without delay, under cardiopulmonary bypass is the ideal treatment for complicated cardiac hydatid cyst with cardiac infarction. An additional medical treatment is necessary to prevent recurrence.

## References

1. Ghrairi H, Khouadja MA, Abouda M, Ammar J, Hantous S, Kilani T, et al. Kyste hydatique du coeur et des vaisseaux, 4 observations. *Presse Med.* 2005; 34: 101-104.
2. Struillou L, Rabaud C, Bischoff N, Preiss MA, May T, Canton P. Complications cardiac hydatid cyst: 2 observations. *Presse Med.* 1997; 26: 1192-1194.
3. Thameur H, Abdelmoula S, Chenik S, Bey M, Ziadi M, Mestiri T, et al. Cardiopericardial hydatid cysts. *World J Surg.* 2001; 25: 58-67.
4. Trehan V, Shah P, Yusuf J, Mukhopadhyay S, Nair GM, Arora R. Thromboembolism: A Rare complication of cardiac hydatidosis. *Indian Heart J.* 2002; 54: 199-201.
5. Molavipour A, Javan H, Moghaddam AA, Dastani M, Abbasi M, Ghahramani S. Combined medical and surgical treatment of intracardiac hydatid cysts in 11 patients. *J CardSurg.* 2010; 25: 143-6.