Clinics in Surgery

Short Communication
Published: 12 Nov, 2018

Bone Borne or Not Bone Borne? Hybrid MMF

*Nikolaos Fanaras and Kathleen Fan**

Department of Oral and Maxillofacial Surgery, King's College Hospital, Denmark

Abstract

Facial trauma can cause severe pain but also emotional distress due to the potential deformity of the facial skeleton. A critical step in the treatment of facial fractures is Inter Maxillary Fixation (IMF). We compared the standard Erich arch bars for IMF to a newer hybrid system that uses bone borne screws for the arch bar fixation, in a busy trauma unit setting. The hybrid system was shown to be time efficient for selected cases and also had higher acceptance among surgeons and patients.

Introduction

The main principles in the treatment of facial fractures are reduction of the bony segments, immobilisation and fixation. Open Reduction and Internal Fixation (ORIF) is used to achieve accurate anatomic reduction of the injured hard tissues while at the same time ensuring proper teeth occlusion and good function [1]. The European Maxillofacial Trauma project, analysing epidemiology of facial trauma in multiple centres across Europe revealed that 42% of the fractures were mandibular, followed by the orbito-zygomatic-maxillary ones with 24% [2]. In current practice use of arch bars for Inter Maxillary Fixation (IMF) is considered the standard [3]. The aim of this pilot study is to compare the traditional methods for IMF to the hybrid MMF (hMMF-Stryker). Hybrid MMF uses self tapping transgingival bone borne screws instead of wires (tooth borne) for the fixation of the arch bar. The rationale behind hMMF is avoidance of increased operating time associated with utilisation of arch bars and hence prolonged operating theatre time, risk of needle stick injury to the operating team and potential discomfort to the patient [4,5].

Materials and Methods

Twenty patients with facial trauma were allocated in two groups that were treated with conventional Erich Arch Bars (EAB) and hMMF respectively. Two performs were used in each group to record the surgeons' and patients' views. Details regarding the site of injury, application time, surgeons' preference and complications have been recorded. Patients also evaluated their treatment by answering a questionnaire at the end of the follow up period.

Results

A breakdown of the injuries treated is shown in Table 1. The average time for the application of the hMMF was 24 mins and 44 mins for Erich arch bars. The time for the overall procedure was 53 mins for the hybrid MMF and 128 for the traditional arch bars. The majority of the surgeons preferred hMMF over Erich arch bars (Figure 1). No glove perforations were recorded when using hMMF while with the EAB glove perforations occurred in 4 cases. In the postoperative period 50% of the hMMF were removed in the clinic without local anaesthetic, reducing the required clinical

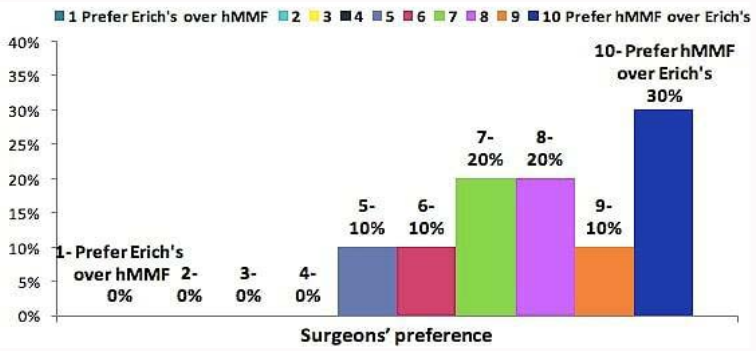

Figure 1: Surgeon's evaluation of the two systems, on a scale from 1 to 10, where 1 is absolute preference of EAB and 10 is preference of hMMF (null observations for the points 1-4 of the scale).

OPEN ACCESS

***Correspondence:**
Kathleen Fan, Department of Oral and Maxillofacial Surgery, King's College Hospital, Bessemer Road, Hill SE5 9RS, Denmark, Tel: 020 3299 5754; Fax: 020 3299 3754; E-mail: kfan@nhs.net

Received Date: *15 Oct 2018*
Accepted Date*: 08 Nov 2018*
Published Date*: 12 Nov 2018*

Citation:
Fanaras N, Fan K. Bone Borne or Not Bone Borne? Hybrid MMF. Clin Surg. 2018; 3: 2214.

Table 1: Location of fractures.

	Condyle	Parasymphysis / Condyle	Bilateral Angle	Le Fort I	Parasymphysis/ Angle	Parasymphysis
ERICH'S	1	2	1	1	2	3
HMMF	4	3	-	3	-	-

Table 2: Patient's reports of pain immediately post operatively and on removal of arch bar.

	Pain Immediately Post Operatively	Pain On Removal Of Arch bar
ERICH'S	8	8
HMMF	5	5

time and simplifying the procedure while all the EAB required local anaesthetic for removal. One screw used in hMMF patients was found to be in contact with the pulp. Surgeons commented on a learning curve with utilisation of hMMF. The use of the hMMF with comminute fractures was found to be more difficult as it did not allow adjustment of the fractured segments once applied. Patients scored their immediate post operative pain an average of 8 out of 10 on a Visual Analogue Scale (VAS) when the EAB was used, and 5 out of 10 with the hMMF. Similarly, the pain on removal was 5 for the hMMF and 8 for the EAB (Table 2).

Conclusion

The hMMF has the advantage of time efficiency for selected cases in a busy maxillofacial unit due to reduction of theatre time. Sharp's injuries were reduced compared to EAB and the hybrid system had a high score of acceptance among surgeons and patients.

References

1. Ellis E III, Miles BA. Fractures of the mandible: A technical perspective. Plast Reconstr Surg. 2007;120(7):76.
2. Boffano P, Roccia F, Zavattero E, Dediol E, Uglešić V, Kovačič Ž, et al. European Maxillofacial Trauma (EURMAT) project: a multicentre and prospective study. J Craniomaxillofac Surg. 2015;43(1):62-70.
3. Hashemi HM, Parhiz A. Complications using intermaxillary fixation screws. J Oral Maxillofac Surg. 2011;69(5):1411-4.
4. Ansari K, Hamlar D, Ho V, Hilger P, Côté D, Aziz T. A comparison of anterior vs posterior isolated mandible fractures treated with intermaxillary fixation screws. Arch Facial Plast Surg. 2011;13(4):266-70.
5. Rai A, Datarkar A, Borle RM. Are maxillomandibular fixation screws a better option than Erich arch bars in achieving maxillomandibular fixation? J Oral and Maxillofac Surg. 2011;69(12):3015-8.