Clinics in Surgery

Research Article
Published: 28 Mar, 2017

Better Survival after Hand-Assisted Laparoscopic Surgery than Conventional Laparotomy for Rectal Cancer: Five-Year Results from a Single Center in Japan

Takayuki Tajima[1], Masaya Mukai[2], Takuya Koike[2], Daiki Yokoyama[2], Shyuji Uda[2], Hisamichi Yoshii[2], Shigeo Higami[2], Hideki Izumi[2], Sayuri Hasegawa[2], Eiji Nomura[2] and Hiroyasu Makuuchi[2]*

[1]Department of Surgery, Tokai University Oiso Hospital, Japan

[2]Department of Surgery, Tokai University Hachioji Hospital, Japan

Abstract

We previously reported an interim analysis of short-term outcomes and 3-year relapse-free survival (RFS) and overall survival (OS) in 111 patients with stage I-III primary rectal cancer who underwent radical curative resection by hand-assisted laparoscopic surgery (HALS; n=57) or conventional laparotomy (CL; n=54). This time, we report the 5-year postoperative RFS and OS for these patients, as well as the pattern of recurrence. Follow-up for 5 years after surgery was possible in 95.5% of all patients (94.7% after HALS and 96.3% after CL, p=N.S.). With regard to background factors, there were no differences between the HALS group and CL group with respect to gender, age, rectal location, resection method, pathological stage, and treatment including postoperative adjuvant therapy. The 5-year relapse-free survival rate (5Y-RFS) was 82.5% in the HALS group versus 67.7% in the CL group (p=0.084) and the 5-year overall survival rate (5Y-OS) was 92.9% in the HALS group versus 73.7% in the CL group (p=0.005). Recurrence was due to liver metastasis (HALS: 7.0%, n=4; CL: 7.4%, n=4) (p=1.000), lung metastasis (HALS: 3.5%, n=2; CL: 9.3%, n=5) (p=0.263), or local intrapelvic recurrence (HALS: 5.3%, n=3; CL 3.7%, n=2) (p=1.000). No patient was converted from HALS to CL. Based on these results, HALS is associated with better survival of rectal cancer patients than CL.HALS allows safe and reliable minimally invasive surgery at a lower cost than pure laparoscopy, suggesting that 3-port HALS with a small (50 mm) abdominal incision can become a standard operative method.

Keywords: Hand-assisted laparoscopic surgery; Conventional laparotomy; Laparoscopy-assisted colorectal surgery; Colorectal cancer; Rectal cancer; Minimally invasive surgery

OPEN ACCESS

Correspondence:
Masaya Mukai, Department of Surgery, Tokai University Hachioji Hospital, Ishikawa-cho1838, Hachioji, Tokyo, Japan,
E-mail: mukai.masaya@hachioji-hosp.ac.jp

Received Date: *14 Dec 2016*
Accepted Date*: 13 Mar 2017*
Published Date*: 28 Mar 2017*

Citation:
Tajima T, Mukai M, Koike T, Yokoyama D, Uda S, Yoshii H, et al. Better Survival after Hand-Assisted Laparoscopic Surgery than Conventional Laparotomy for Rectal Cancer: Five-Year Results from a Single Center in Japan. Clin Surg. 2017; 2: 1368.

Abbreviations

HALS: Hand-Assisted Laparoscopic Surgery; CL: Conventional Laparotomy; Pure-Lap: Pure Laparoscopy-Assisted Colorectal Surgery; TME: Total Mesorectal Excision; TSME: Tumor-Specific Mesorectal Excision

Introduction

Currently, pure laparoscopy-assisted colorectal surgery (pure-Lap) has become very popular in Japan. In general, 5-6 ports including a port for the laparoscope are required for such operations, usually with a small incision of 30-40 mm.Since the operation is mainly performed using 4 forceps, at least 2 surgeons skilled at pure-Lap are needed, and the number of anesthesiologists and theater staff required represent a problem together with the long operating time. In addition to the technical training and education required for pure-Lap, concerns about its high cost remain unresolved [1]. Pure-Lap for rectal cancer is technically difficult, and there have been several reports warning about the importance of securing a circumferential resection margin (CRM) at the posterior surface of the tumor as well as a safe anal margin (anal wedge; AW) [2,3]. In contrast, when conventional laparotomy (CL) is performed for lower rectal cancer, the colorectal surgeon can use the left hand to operate on the region from the pelvic surface to the posterior surface of the tumor/anal region. Conventional left hand manipulation is also possible with hand-assisted laparoscopic surgery (HALS), and the camera monitor provides clear and safe visualization from the prostatic apex to the deep anterior wall of the pelvis and the pelvic floor in the vicinity of the membranous urethra, a region that is difficult to observe during CL [4-7]. Thus, HALS represents a hybrid surgical

Table 1: Profile of the HALS group and CL group.

		HALS(n=57)	Conventional(n=54)	P value (X^2)
Sex	Male	75.4% (43/57)	64.3% (35/54)	P=0.221
	Female	24.6% (14/57)	35.2% (19/54)	
Age	Mean	65.4	67.0	P=0.095
	Median	65 (55-81)	68.5 (35-92)	
Location	Rs	35.1% (20/57)	37.0% (20/54)	P=0.831
	Ra	36.8% (21/57)	25.9% (14/54)	P=0.216
	Rb	28.1% (16/57)	37.0% (20/54)	P=0.313
Resection method	Anterior resection	19.3% (11/57)	22.2% (12/54)	P=0.704
	Low anterior resection	68.4% (39/57)	61.1% (33/54)	P=0.420
	Miles' operation	12.3% (7/57)	16.7% (9/54)	P=0.511
Pathological Stage	Stage I	29.8% (17/57)	18.5% (10/54)	P=0.165
	Stage II	24.6% (14/57)	37.0% (20/54)	P=0.154
	Stage III	45.6% (26/57)	44.4% (24/54)	P=0.901

technique positioned between CL and pure-Lap. We have previously reported that the short-term outcome, complications, and survival are comparable after HALS and CL [1,8,9]. However, there have been no detailed single-center comparisons of HALS and CL with regard to long-term survival and the pattern of recurrence in patients with rectal cancer. Accordingly, this study was performed to compare long-term data on survival and recurrence in rectal cancer patients treated by HALS or CL.

Patients and Methods

Institutional review board

This retrospective study was approved by the IRB of Tokai University School of Medicine (Approval No. 14R-001).

Patient profile

Patients with stage I-III primary rectal cancer who underwent radical resection were enrolled in this study. The CL group included 54 patients who underwent conventional CL prior to introduction of HALS (April 2003 onwards to June 2007), and the HALS group comprised 57 patients who underwent HALS from July 2007 onwards. There were no differences between the two groups with regard to gender, age, rectal location, resection method, pathological stage, and treatment including postoperative adjuvant therapy. The 54 patients in the CL group received the same postoperative adjuvant chemotherapy as the HALS group at each stage and were selected as stage-matched historical controls (Table 1). Only surgery and no adjuvant therapy was performed for stage I disease, while oral anticancer agents were administered to stage II patients (tegafur/uracil; UFT) for 1 year, and oral 5FU+LV/DIV and/or UFT/Uzel were administered to stage III patients for 1 year [10-13]. Screening for recurrence was based on measurement of tumor markers, including CEA/CA19-9, and the time when a recurrent lesion was found by US and CT was defined as the date of recurrence. Indications for HALS. The indications were: 1) no history of major laparotomy, 2) P.S. of 0-2, 3) age of 75 years or younger, 4) no severe cardiopulmonary complications and ability to tolerate general anesthesia for approximately 3 hours in a posture with the head lowered and the legs spread, 5) no invasion of other organs (T4) or lateral lymph node metastasis, and 6) tumor not filling the pelvic cavity. In both groups, patients underwent surgical resection first and patients treated with chemo-radiotherapy (CRT) preoperatively were excluded. Operation theater set-up and abdominal ports for 3-port HALS. A Lap-disc (Hakkou Co., Ltd. Nagano, Japan) was placed in a median vertical incision of approximately 50mm in the umbilical

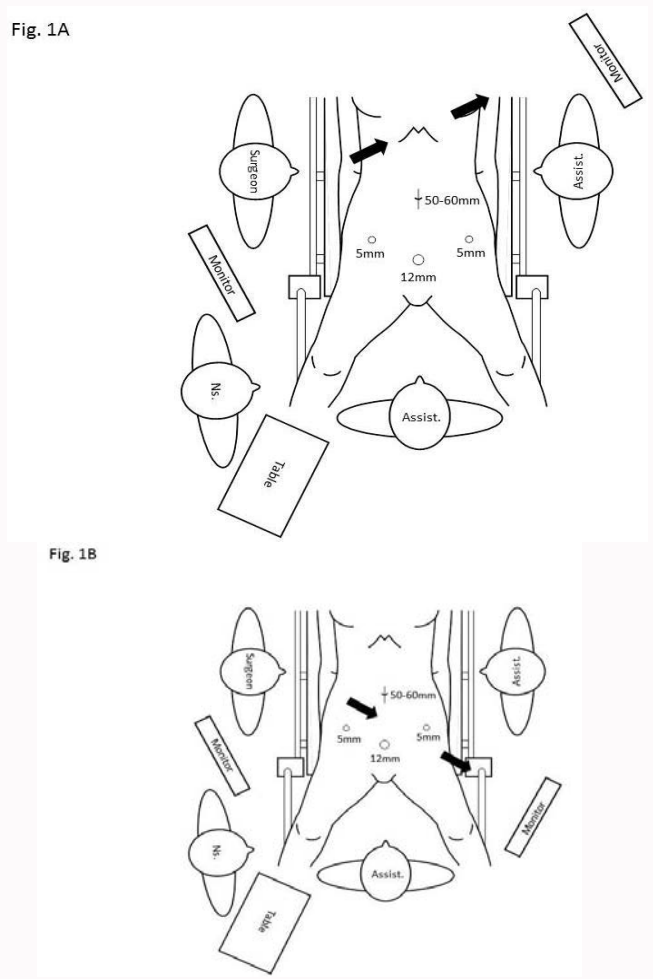

Figure 1A and 1B: A total of 3 ports (5mm/12mm/5mm) are inserted centered on the surgeon's left hand. For mobilization of the sigmoid colon to rectal resection, the monitor is set above the patient's left shoulder and behind the surgeon's right shoulder. When operating on the pelvic floor, the monitor is moved to near the patient's left leg.

region, and then 3 ports (2 x 5 mm, 1 x 12 mm) were inserted toward the pelvic cavity with a focus on the Lap-disc (Figure 1A). A 5 mm port for operating was inserted into the left upper anterior iliac region (drain tube region) under guidance of the left hand, and then a 12 mm port for pneumoperitoneum was placed at the midline of the superior pubic margin with guidance by the left hand so as not to damage the dome of the bladder. Finally, a 5mm port for operating was inserted into the right upper anterior iliac region (Figure 1B). CL was performed conventionally with a lower abdominal median incision (approximately 30cm or longer) from the superior pubic margin to 5cm or more into the supraumbilical region.

Procedure for 3-port HALS

1) Sigmoid colon mobilization and confirmation of the ureters

After careful intraperitoneal observation, incision and dissection were started using the outside approach from the sigmoid colon toward the left paracolic sulcus, and the left ureter was confirmed. The descending colon was mobilized from the sigmoid mesocolon to the splenic flexure, and the descending aorta (Ao)/inferior mesenteric artery (IMA) were confirmed. The root of the IMA was identified between the Ao and IMA, the sigmoid mesocolon was mobilized in nerve-sparing fashion and fenestrated toward the right common iliac artery and right ureter, and dissection was advanced to the pelvic surface while placing the left hand between the Ao and IMA. The extent of resection was D2 or 3 in accordance with the Japanese Classification of Colorectal Carcinoma. Ligation and transaction was done with the HALS procedure at the IMA root with preservation of the left colic artery blood vessel (Figure 1A).

2) Complete total mesorectal excision

Total mesorectal excision (TME)/tumor specific mesorectal excision (TSME) involves confirming the blood flow to the reconstructed colon, securing a sufficient margin without tension on the an astomosis, and transecting the colon with a stapler directed toward the pelvic floor through the median 12 mm port. When the monitor is moved from above the patient's left shoulder to a position near the left leg and a flexible 5 mm scope is used, it is possible to work the camera from all 3 ports, which is very convenient (Figure 1B). The peritoneum in the pouch of Douglas is crossed while applying sufficient counter traction using a retractor and the entire circumference is fenestrated toward the lower rectum. The left and right ureters are dissected laterally, the internal iliac vein anteriorly, and the sacrum posteriorly to prepare for nerve-sparing surgery and dissection then proceeds to the lower bladder/trigone. In men, when the left and right seminal vesicles are exposed, Denonvielliers' fascia is dissected carefully so as not to damage the seminal vesicles/vas deferens and dissection then proceeds to the posterior face of the prostate (vaginal wall in women). Dissection of the pelvic floor and lymph nodes is performed for TME/TSME, and the anal side of the tumor is reached to completely expose the pelvic floor muscles. In particular, resection of the mesorectum in the posterior side of the tumor should be performed completely (CRM≥1 mm), AW of 20 mm or more should be secured, and the entire circumference should be dissected/exposed while not damaging the rectum (Figure 1B).

3) Very low anastomos is or Miles' operation (including RS anterior resection)

Rectal blocking forceps are inserted from the median 12 mm port, and rectal lavage is performed after rectal blockage. After sufficient incision/dissection of the posterior face of the prostate (posterior vaginal wall), the prostatic apex (anal region of the vaginal wall) as far as the membranous urethra (male), the rectum is respected and very low anastomosis (DST/I.O. anastomosis) is performed. After confirming hemostasis, a drain is inserted from the anterior left iliac port to the vicinity of the anastomosis and a loop stomais constructed. Otherwise, the pelvic floor muscles are respected/dissected laterally for removal of the anal/perineal region, the perineal fat is confirmed on both sides of anus, and U-shaped incision/dissection is performed from the apex of the coccyx to the anal/perineal region toward the fatty layer in the 6 o'clock direction of the anal canal. With a focus on the anus, a margin of 3cm or more is secured, and a circular incision is made in the perineal skin. At the dissection plane between the external anal sphincter and the perianal fat, incision/dissection is performed toward the dissection line of the pelvic floor muscles achieved by the HALS procedure. The peritoneal cavity is accessed from the front of the coccyx while taking care to avoid urethral injury at the prostatic apex in men and injury of the posterior vaginal wall in women, and the rectal/anal resection is completed. After confirming hemostasis of the periprostatic (perivaginal) region and the resection margin of the pelvic floor muscles, a drain is placed from the left perineal region to the lesser pelvic cavity, a single-port stoma is constructed via the retroperitoneum in a similar manner to CL, and the incision is closed [1,14].

Statistical analysis

Fifty-seven patients meeting the above-mentioned requirements underwent HALS (HALS group: stage I: 17, stage II: 14, stage III: 26) and 54 patients underwent CL (CL group: stage I: 10, stage II: 20, stage III: 24) (Table 1). Postoperative 5-year relapse-free survival (5Y-RFS) and 5-year overall survival (5Y-OS) were compared between these 2 groups, and the pattern of recurrence was also investigated. Statistical analysis was performed with SPSS version 17 (IBM SPSS, Armork, NY, USA) and $p<0.05$ was considered to indicate a significant difference.

Results

Follow-up for 5 years after surgery was possible in 95.5% of all patients (HALS; 94.7%, CL; 96.3%) (Not significant: data not shown). The 5Y-RFS was 82.5% in the HALS group and 67.7% in the CL group (p=0.084) (Figure 2A). In addition, 5Y-OS was 92.9% in the HALS group and 73.7% in the CL group (p=0.005) (Figure 2B). Recurrence occurred most frequently in the liver (HALS group: 7.0%, n=4/CL group: 7.4%, n=4) (p=1.000), followed by the lung (HALS group: 3.5%, n=2 /CL group: 9.3%, n=5) (p=0.263) and then local intrapelvic recurrence (HALS group: 5.3%, n=3/CL group: 3.7%, n=2) (p=1.000) (Table 2). None of the patients required conversion from HALS to CL.

Discussion

Since iatrogenic injury to the liver and pancreas has recently become a problem during laparoscopic surgery in Japan, the safety of laparoscopic procedures and their management has attracted wide attention even outside the medical field. In addition, the detailed advantages and disadvantages of laparoscopic surgery are becoming more apparent, driven by data from gastrointestinal surgery (on the esophagus, stomach, and large intestine), leading to discussion about optimal patient-oriented minimally invasive surgery. HALS, which utilizes the same left-hand manipulation as CL, has again become a focus of public attention in Japan, including in the field of liver/pancreas surgery. Compared to pure-Lap, HALS has the

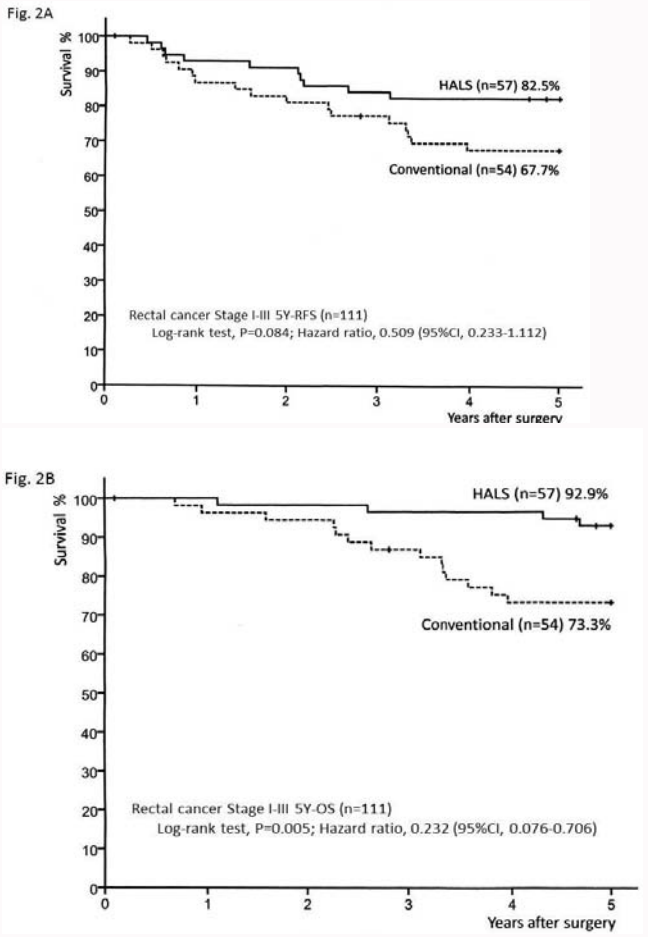

Figure 2A and 2B: 5Y-RFS was 78.9% in the HALS group and 73.3% in the CL group (p=0.874). 5Y-OS was 92.8% in the HALS group and 73.3% in the CL group (p=0.553).

following advantages: 1) a shorter operating time as an extension of laparotomy; 2) it allows safe and reliable palpation, information can be obtained from the back of the hand, and perception of deep structures is available immediately; 3) surgery can be performed gently and smoothly even for large and heavy tumors; 4) extensive training is not required, 5) it is less costly than pure-Lap, 6) although the incision is approximately 10-20 mm longer than for pure-Lap, the conversion rate to open surgery is lower; and 7) it is comparable to CL in all other points including the hospital stay and complications [8,9]. Under these circumstances, we have performed HALS in over 500 patients with colorectal cancer from July 2007 and have obtained favorable results. A small incision of approximately 45-55 mm is made, and 1-2 surgeons perform 2-port (5 mm/5 mm) surgery for the colon or 2-3 surgeons perform 3-port (5 mm/12 mm/5 mm) surgery for the rectum. HALS can be applied to 7 different operative methods, including right hemicolectomy, Miles' operation, and total colorectal resection (IPAA). The operating time is markedly shorter than for pure-Lap and the conversion rate to CL was 5.1% among all colorectal cancer patients (5/98 patients, data not shown) in our initial analysis. Previous comparisons between HALS and CL have revealed significantly less blood loss in stage I/II patients with HALS and a significantly shorter hospital stay in stage III patients [8,9]. Based on the above results, we consider that HALS is not just a bridging technique for use during the period of conversion from conventional open surgery to laparoscopic surgery, and is also not just an optional procedure before conversion to open surgery, but instead is an alternate form of minimally invasive surgery. Therefore, HALS is considered to be a useful surgical option that should be reconsidered in the current Japanese medical environment where the number of surgeons and anesthesiologists is decreasing.

Table 2: Pattern of recurrence of rectal cancer in the HALS group and the CL group.

Site of recurrence	HALS (n=57)	Conventional (n=54)	P value (Fisher's exact test)
Liver	7.0% (4/57)	7.4% (4/54)	P=1.000
Lung	3.5% (2/57)	9.3% (5/54)	P=0.263
Localpelvic	5.3%(3/57)	3.7% (2/54)	P=1.000
Others	1.8% (1/57)	5.6% (3/54)	P=0.355
Total	17.5% (10/57)	25.9% (14/54)	P=0.358

With regard to rectal cancer, pure-Lap for lower rectal cancer in the vicinity of the anus is technically difficult, and left-hand manipulation toward the deep pelvic floor as can be done with HALS or CL is essential. Large and heavy tumors can be manipulated gently with HALS, and applying strong traction in the cephalad direction from the pelvic floor is also possible. Unlike CL, it is possible to dissect (complete TME) the entire circumference of the rectum safely with HALS while securing a sufficient margin at the posterior face of the tumor using the monitor and crossing the front of the sacrum. Accordingly, we consider that HALS is a reasonable hybrid operation for lower rectal cancer that combines the left-hand manipulation of CL and laparoscopic procedures via monitor. Although there may occasionally be patients who require open conversion, no patients were converted to CL in the present series. Why was survival influenced by HALS? Although no significant difference was observed, it is undeniable there were more complications and a slightly higher age in the CL group (p=0.095), and a tendency for a difference of 5Y-RFS was also observed (p=0.084). Although the presence/absence of wound infection and the degree of surgical site infections should also be considered, we consider that there will inevitably be differences of wound healing, infection, and dehiscence between wounds of 20 cm or longer and those of less than 5 cm. Factors with an influence are assumed to be early postoperative wound infection, transient bacteremia, management of wound infection with antibiotics, induction of inflammatory cytokines, and reduction of nonspecific immunity [15,16]. In addition, initiation of adjuvant chemotherapy in the outpatient clinic maybe delayed due to an extended hospital stay. Even in stage II or III patients, isolated cancer cells are circulating in the body after surgery [17,18]. For prevention of metastasis/recurrence of cancer, it is most important to destroy these residual isolated cancer cells at an early stage after resection of the primary tumor [19,20]. Therefore, a surgery with a short operating time like CL, a smaller wound like pure-Lap, and sufficient CRM/AW is minimally invasive surgery in the real sense. It is speculated that earlier initiation of postoperative adjuvant chemotherapy in stage II/III patients was achieved after rectal HALS. Histological investigation on CRM/AW is currently being conducted in these subjects to perform comparison between HALS and CL [2.3]. Based on these results, HALS represents safe and reliable minimally invasive surgery for rectal cancer that achieves better survival than CL at a lower cost than pure-Lap. The 3-port HALS procedure we are conducting for rectal cancer is a reasonable surgical option that should be reconsidered in the Japanese medical environment where the number of surgeons/anesthesiologists has been decreasing, and is

also a superior hybrid procedure that may be established as a standard surgical method for lower rectal cancer.

Acknowledgement

This study was supported by grants from the Japan HALS Research Group(HALS-RG Hp; tes.tokai.ac.jp/oncs-hp/hals-rg/group.htm, Head office; Ex. 3049, Tokai University Hachioji Hospital, Hachioji, Tokyo, Japan), the Occult Neoplastic Cells Research and Study Group (ONCs-RSG Hp; tes.tokai.ac.jp/oncs-hp/, Tokai University Hachioji Hospital, Hachioji, Tokyo, Japan), and the Research and Study Program of Tokai University Educational System General Research Organization (Tokai University School of Medicine, Isehara, Kanagawa, Japan).

References

1. Mukai M, Kishima K, Tajima T, Hoshikawa T, Yazawa N, Fukumitsu H, et al. Efficacy of Hybrid 2-port hand-assisted laparoscopic surgery (Mukai's operation) for patients with primary colorectal cancer. Oncol Rep. 2009;22:893-9.
2. Fleshman J, Branda M, Sargent DJ, Boller AM, George V, ABBAS M, et al. Effect of Laparoscopic-Assisted Resection vs. Open Resectionof Stage II or III Rectal Cancer on Pathologic Outcomes, The ACOSOG Z6051 Randomized Clinical Trial. JAMA. 2015;314:1346-55.
3. Stevenson ARL, Solomon MJ, Lumley JW, Hewett P, Clouston AD, Gebski VJ, et al. Effect of Laparoscopic-Assisted Resection vs. Open Resectionon Pathological Outcomes in Rectal Cancer, The A La Ca RT Randomized Clinical Trial. JAMA. 2015;314:1356-63.
4. Kusminsky RE, Boland JP, Tiley EH, Deluca JA. Hand-assisted laparoscopic splenectomy. Surg Laparosc Endosc. 1995;5:463-7.
5. Ou H. Laparoscopic-assisted mini-laparotomy with colectomy. Dis Colon Rectum.1995;38:324-6.
6. Kusminsky RE, Boland JP, Tiley EH, Ou H. Hand-assisted laparoscopic surgery (letter;comment). Dis Colon Rectum. 1996;39:111.
7. Bemelman WA, Ringers J, Meijer DW, de Wit CWM, Bannenberg JJG. Laparoscopic-assisted colectomy with the dexterity pneumo sleeve. Dis Colon Rectum. 1996;39:S59-61.
8. Takayuki Tajima, Masaya Mukai, Masashi Yamazaki, Shigeo Higami, Souichirou Yamamoto, Sayuri Hasegawa, et al. Comparison of hand-assisted laparoscopic surgery and conventional laparotpmy for colorectal cancer:Interim results from a single institution. Oncol Lett. 2014;8:627-32.
9. Takayuki Tajima, Masaya Mukai, Wataru Noguchi, Shigeo Higami, Shuuji Uda, Souichirou Yamamoto, et al. Comparison of hand assisted laparoscopic surgery and conventional laparotomy for rectal cancer:Interim results from a single center. Mol & Clin Oncol. 2015;3:533-8.
10. Masaya Mukai, Takayuki Tajima, Hisao Nakasaki, Shinkichi Sato, Kyoji Ogoshi, Hiroyasu Makuuchi. Efficacy of postoperative adjuvant oral immunochemotherapy in patients with Dukes' B colorectal cancer. Ann Cancer Res Therap. 2003;11:201-14.
11. Masaya Mukai, Takayuki Tajima, Hisao Nakasaki, Shinkichi Sato, Kyoji Ogoshi, Hiroyasu Makuuchi. Efficacy of postoperative adjuvant oral immunochemotherapy in patients with Dukes' C colorectal cancer. Ann Cancer Res Therap. 2003;11:215-29.
12. Isao Ito, Masaya Mukai, Hiromi Ninomiya, Kyoko Kishima, Kazutoshi Tsuchiya, Takayuki Tajima, et al. Comparison between intravenous and oral postoperative adjuvant immunochemotherapy in patients with stage II colorectal cancer. Oncol Rep. 2008;20:1189-94.
13. Isao Ito, Masaya Mukai, Hiromi Ninomiya, Kyoko Kishima, Kazutoshi Tsuchiya, Takayuki Tajima, et al. Comparison between intravenous and oral postoperative adjuvant immunochemotherapy in patients with stage III colorectal cancer. Oncol Rep. 2008;20:1521-6.
14. Masaya Mukai, Yasutomo Sekido, Tatsuhiko Hoshikawa, Naoki Yazawa, Hiroshi Fukumitsu, Kazutake Okada, et al. Efficacy of 2-stage treatment (Mukai's method) using Hybrid 2-port HALS (Mukai's operation)for complete bowel obstruction by left colon cancer or rectal cancer. Oncol Rep. 2010;24:25-30.
15. Veenhof AA, Sietses C, von Blomberg BM, van Hoogstraten IM, vd Pas MH, Meijerink WJ, et al. The surgical stress response and postoperative immune function after laparoscopic or conventional total mesorectal excision in rectal cancer:a randomized trial. Int J Colorectal Dis. 2011;53-9.
16. Joris J, Cigarini I, Legrand M, Jacquet N, De Groote D, Franchimont P, et al. Metabolic and respiratory changes aftercholecystectomy performed via laparotomy orlaparoscopy. Br J Anaesth.1992;69:341-5.
17. Masaya Mukai, Shinkichi Sato, Nobukazu Komatsu, Tomomi Nishida, Kazuaki Shiba, Isao Ito, et al. Correlation between occult neoplastic cells in the lymph node sinuses and recurrence in patients with Dukes' C colorectal cancer. Oncol Rep.2003;10:1165-9.
18. Masaya Mukai, Shinkichi Sato, Nobukazu Komatsu, Tomomi Nishida, Kazuaki Shiba, Isao Ito, et al. Correlation between occult neoplastic cells in the lymph node sinuses and recurrence in patients with curatively resected Dukes' B colorectal cancer. Oncol Rep. 2003;10:1177-81.
19. Yasutomo Sekido, Masaya Mukai, Kyoko Kishima, Takayuki Tajima, Tatsuhiko Hoshikawa, Masato Nakamura, et al. Occult neoplastic cells in the lymph node sinuses and recurrence/metastasis of stage II/Dukes' B colorectal cancer. Oncol Rep. 2011;25:69-73.
20. Yasutomo Sekido, Masaya Mukai, Kyoko Kishima, Takayuki Tajima, Tatsuhiko Hoshikawa, Masato Nakamura, et al. Occult neoplastic cells in the lymph node sinuses and recurrence/metastasis of stage III/Dukes' C colorectal cancer. Oncol Rep. 2011;25:915-9.