Clinics in Surgery

Research Article
Published: 27 Apr, 2017

Acute Diverticulitis with and without Microperforation: Should they be Treated the Same?

Ron Dibble[1], Bassam Al-Mamoori[2] and Juan L Poggio[3]*

[1]Department of Colorectal Surgery, Drexel University College of Medicine, Philadelphia, 19129, USA

[2]Department of Radiology Drexel University College of Medicine, Philadelphia, USA

[3]Department of Surgery, Drexel University College of Medicine, Philadelphia, USA

Abstract

Background: The use of Computed Tomography imaging has enabled clinicians to visualize a subset of uncomplicated diverticulitis known as microperforation. Microperforation of a diverticulum is visualized as the development of focal contained collections appearing as small extraluminal pockets of air or extravasation of contrast material. The goal of our study is to determine if acute diverticulitis with microperforation should be clinically treated the same as uncomplicated acute diverticulitis or if they differ with respect to morbidity.

Methods: A retrospective analysis was conducted on 141 patients with a primary diagnosis of acute uncomplicated diverticulitis with or without microperforation via computed tomography imaging. The data was obtained from Hahnemann University Hospital Medical Records dating from 2008-2015. Readmission within 30 days for failure to respond to medical therapy was the primary outcome variable.

Results: The sample included 141 patients diagnosed with acute diverticulitis, 32 of which had a diagnosis of microperforation. The overall 30-day readmission rate was 6.38%. No patient in this study required surgery within 30 days. Univariate analysis of readmission rates between patients diagnosed with acute diverticulitis with microperforation and without microperforation revealed an odds ratio of 0.97, 95% CI (0.19-4.93, p=0.97).

Conclusion: Acute diverticulitis with microperforation is not associated with an increased rate of readmission or need for surgery when compared to patients diagnosed with uncomplicated acute diverticulitis without microperforation.

OPEN ACCESS

Correspondence:
Ron Dibble, Department of Colorectal Surgery, Drexel University College of Medicine, 1204 Walnut Circle Drive, Portage, PA 15946, USA. Tel: (814) 421-8370;
E-mail: ronalddibble@gmail.com

Received Date: *13 Feb 2017*
Accepted Date*: 20 Apr 2017*
Published Date*: 27 Apr 2017*

Citation:
Dibble R, Al-Mamoori B, Poggio JL. Acute Diverticulitis with and without Microperforation: Should they be Treated the Same?. Clin Surg. 2017; 2: 1443.

Introduction

Diverticulosis is reported in 43% of patients undergoing routine colonoscopy [1]. The diagnosis of diverticulitis can be made on history and physical along with an elevated white blood cell count, however, studies have questioned the reliability of leukocytosis in the diagnosis [2]. Computed tomography (CT) is the radiographic test of choice in diverticulitis. With the use of a CT scan, Jacobs et al. [3] found the diagnosis of acute diverticulitis has a sensitivity of 93-97% and a specificity approaching 100%. In addition, the use of a CT scan has enabled clinicians to visualize a subset of uncomplicated diverticulitis known as microperforation. Microperforation of a diverticulum often leads to the development of focal contained collections appearing as small extraluminal pockets of air, gas bubbles, or contained extravasation of rectal contrast material [4]. Figure 1 shows typical CT findings of a patient with microperforated diverticulitis.

Complicated diverticulitis may require more invasive treatment modalities such as percutaneous drainage or colectomy whereas uncomplicated diverticulitis is often managed medically with antibiotics. In addition, patients with microperforation are generally medically treated the same as patients with acute uncomplicated diverticulitis. Current research focuses mainly on the more invasive treatments and their outcomes; however 80% of cases of first-time diverticulitis lie in the uncomplicated category [5]. To date, there are no studies that focus on the outcomes of patients with acute uncomplicated diverticulitis with microperforation. The goal of our study is to determine if patients with acute uncomplicated diverticulitis with microperforation should indeed be treated the same as patients without microperforation or if they differ with respect to readmission rates, complications, and need for surgery. In addition, if they differ, we hope to determine factors that may contribute to that difference in an effort to guide clinical decision-making.

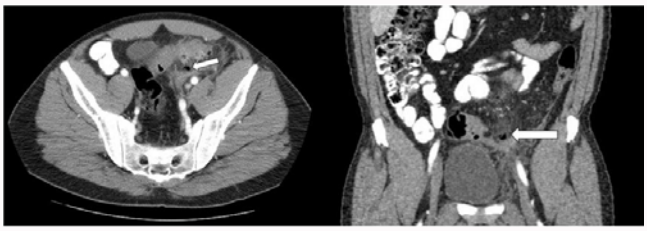

Figure 1: Abdominal CT scans demonstrating the radiographic features of acute uncomplicated diverticulitis with microperforation. White arrows indicate areas of microperforation.

Table 1: Demographic factors of study population subgroups.

	Microperforation	Without Microperforation
Median Age (years)	50	61
Sex		
Male	59% n=19)	32% (35)
Female	41% (13)	(68% (74)
Race		
African American	45% (15)	57% (62)
White	36% (11)	33% (36)
Other	19% (6)	10% (11)
Average BMI kg/m^2)	32.8	32
Smoking Prevalence	42% (13)	49% (54)
Hypertension	29% (9)	35% (38)

Methods

After obtaining IRB approval, Hahnemann University Hospital medical records were reviewed to select patients with a primary admission diagnosis of acute diverticulitis. Exclusion criteria included: prior colectomy, significant comorbidities that could interfere with diagnosis or treatment (Crohn's disease and ulcerative colitis), nonspecific CT findings (diverticulitis vs. colitis), and antibiotic noncompliance. 141 patients were identified between 2008 and 2015 that met inclusion criteria. A radiologist from this institution reviewed all CT scans for the presence of microperforation. BMI in kilograms per square meter was calculated using height and weight data. The major outcome variables were readmission within 30 days of discharge with similar or worsened symptomology and need for surgery or percutaneous drainage. In addition to demographic information, data was also collected on BMI, antibiotic course, blood pressure, fever, leukocytosis, abdominal pain, and smoking status. Smoking was defined as anyone that had a history of smoking within the last 5 years.

Results

Of the 141 cases of acute uncomplicated colonic diverticulitis, 32 were found to have microperforation. The overall readmission rate was 6.38%, 6.25% for microperforation, and 6.42% for patients without microperforation, P=0.97 (Table 1). Of the 9 readmission cases, 4 chose to undergo elective colectomy at a later date due to multiple readmissions over the course of a year. The cases of elective colectomy were split 2 and 2 between microperforation and no microperforation. Univariate analysis of readmission rates between patients diagnosed with acute diverticulitis with microperforation and without microperforation revealed a statistically insignificant odds ratio of 0.97, 95% CI (0.19-4.93, p=0.97). The median length of stay for microperforation was 4 days and without microperforation was 2 days. Compares the length of antibiotic course between the three groups.

Table 2: Readmission rate and odds ratio.

	All	Microperforation	Without Microperforation
Readmission rate	6.38%	6.25%	6.42%
Odds ratio (95% CI):	0.97 (0.19-4.93, p=0.97)		

Table 3: Clinical characteristics of the study population.

	All	Microperforation	Without Microperforation
Length of stay (days)	3	4	3
Fever	6.40%	12.90%	4.60%
Odds ratio (95% CI):	3.08 (0.77-12.26, p=0.11)		
Leukocytosis	44%	58%	40%
Odds ratio (95% CI):	2.05 (0.91-4.60, p=0.083		

Table 2 includes demographic characteristics for two groups: patients with and without microperforation. The population had a median age of 58. Women comprised 62% of the study population but only 41% of the cases of microperforation. Male patients with diverticulitis were 3 times more likely to have microperforation than female patients (OR: 3.09, 95% CI 1.37-6.96, P=0.0065). The most common race was African American, making up 54% of the study population. BMI did not differ significantly between groups, however, the average BMI was 32.3, and falling into the category of obese (the lowest BMI within the study was 29.0 falling just into the category of overweight).

The cases of diverticulitis were divided between the descending/sigmoid colon (91.5%), cecum (4.7%), and ascending colon (3.8%). Fever was present in 12.9% of patients with microperforation and 4.6% without evidence of microperforation (OR: 3.08, 95% CI 0.77-12.26, p=0.11). Leukocytosis was present in 58% of patients with microperforation and 40% without evidence of microperforation (OR: 2.05, 95% CI 0.91-4.60, p=0.083) (Table 3). All patients from these two groups were discharged home without requiring surgery during that initial hospital stay.

Discussion

Our study determined that patients diagnosed with acute uncomplicated diverticulitis with microperforation were not associated with an increased risk of readmission compared to patients without microperforation. In addition, the readmission rate was 6.38% overall and the microperforation group had a slightly lower readmission rate of 6.25%. Length of stay was not significantly different either, with the microperforation group staying only one additional day on average. Interestingly, patients readmitted for diverticulitis had a length of stay one day shorter than the median overall length of stay. The groups did not differ significantly in the length of antibiotic course overall, length of intravenous antibiotics, or length of oral antibiotics. From this we can conclude that the patients with microperforation were readmitted at a similar rate to those without microperforation because they were clinically similar, not because they were treated differently with respect to antibiotics. Furthermore, neither group required emergent surgery within 30 days.

Leukocytosis and fever are characteristics generally associated with diverticulitis; however, our study found that only about half of the

patients displayed these characteristics (48% and 44% respectively). In addition, both leukocytosis and fever were more common in patients with microperforation. Our data is consistent with other studies, which have questioned the reliability of leukocytosis in the diagnosis of diverticulitis [6].

Many of the demographic factors in our study are consistent with other large, multi-center studies. The age and sex dependent nature of diverticulitis is highlighted well in our data. The microperforation group was younger and male predominant compared to the group without microperforation, which tended to be older and female predominate. These results are consistent with the study done by Nguyen et al. [7]. The average BMI for our study is considered obese (lowest BMI being 29.0) which is consistent with the data from Strate et al. [8]. Nearly half of our study population smoked, a finding that is corroborated by Hjern et al. [9]. Lastly, sigmoid/descending colon diverticulitis comprised 91.5% of the cases, which is consistent with the data from Hughes et al. [10].

Limitations

While this is the first study, to our knowledge, comparing acute diverticulitis with and without microperforation, this study has two main limitations: sample size and being a single-center study. However, many of the demographic factors in our study are consistent with the results of larger, multi-center studies on diverticulitis, which implies that our study population may be representative of the population of patients with acute uncomplicated diverticulitis as a whole.

Conclusion

Acute diverticulitis with microperforation did not show a statistically significant difference in rate of readmission when compared to patients diagnosed with acute diverticulitis without microperforation. Furthermore, neither group required emergent surgery within 30 days. Therefore, because the subjects within the study were not treated differently with regard to antibiotic course, the data suggests that the two groups should be treated as the same.

Author Contributions

Ron Dibble contributed to data gathering, statistical analysis, and was the primary author. Bassam Al-Mamoori read the computed tomography scans for our study. Juan Lucas Poggio developed the basis of the study, provided guidance while carrying out the study, and was the primary editor of the paper.

References

1. Everhart JE, Ruhl CE. Burden of digestive disease in the United States part II: lower gastrointestinal diseases. Gastroenterology. 2009;136:741-54.
2. Ambrosetti P, Robert JH, Witzig JA, Mirescu D, Mathey P, Borst F, et al. Acute left colonic diverticulitis: a prospective analysis of 226 consecutive cases. Surgery. 1994;115(5):546-50.
3. Jacobs DO. Clinical practice. Diverticulitis. N Engl J Med. 2007;357(20):2057-66.
4. Snyder MJ. Imaging of colonic diverticular disease. Clin Colon Rectal Surg. 2004;17(3):155-62.
5. Anaya DA, Flum DR. Risk of emergency colectomy and colostomy in patients with diverticular disease. Arch Surg. 2005;140(7):681-5.
6. Hollink N, Dzabic M, Wolmer N, Boström L, Rahbar A. High prevalence of an active human cytomegalovirus infection in patients with colonic diverticulitis. J Clin Virol. 2007;40(2):116-9.
7. Nguyen GC, Sam J, Anand N. Epidemiological trends and geographic variation in hospital admissions for diverticulitis in the United States. World J Gastroenterol. 2011;17(12):1600-5.
8. Strate LL, Liu YL, Aldoori WH, Syngal S, Giovannucci EL. Obesity increases the risks of diverticulitis and diverticular bleeding. Gastroenterology. 2009;136(1):115-122.
9. Hjern F, Wolk A, Håkansson N. Smoking and the risk of diverticular disease in women. Br J Surg. 2011;98(7):997-1002.
10. Hughes LE. Postmortem survey of diverticular disease of the colon. I. Diverticulosis and diverticulitis. Gut. 1969;10(5):336-44.