



A Rare Case of Pulmonary Hydatid Cysts with Presentation of Pleural Effusion

Manouchehr Aghajanzadeh¹, Ali Alavi Foman², Alirza Jafarnegad², Azita Tangestaninejad² and Yousha Pourahmad^{3*}

¹Department of Thoracic Surgery, Guilan University of Medical Sciences, Iran

²Department of Pulmonology, Guilan University of Medical Sciences, Iran

³Department of Internal Medicine, Inflammatory Lung Diseases Research Center, Guilan University of Medical Sciences, Iran

Abstract

Pleural effusion in pulmonary hydatid cysts is a very rare complication and its diagnosis and treatment is still a complex problem. We report an interesting case with symptoms of left-sided chest pain, cyanosis and dyspnea, which was referred from local hospital and chest radiograph showed pleural effusion. Despite insertion of chest tube we saw persistent air leaks with lung collapse in control chest radiograph. CT-scan of chest performed in our center and showed left side and a circular lesion in central of pleural effusion. So we planned surgery for the patient. During surgery, we found pulmonary hydatid cysts that were ruptured with the presence of debris and laminated membrane in the lesion and pleural effusion. A diagnosis of hydatid cyst made on histopathological tests. Patient was discharged in good condition on the sixth postoperative day with the prescription of Albendazole [800 mg] daily. Ruptured pulmonary hydatid cyst is one of the differential diagnosis of pleural effusion and surgery is indicated in these cases.

OPEN ACCESS

*Correspondence:

Yousha Pourahmadi, Department of Internal Medicine, Inflammatory Lung Diseases Research Center, Razi Hospital, School of Medicine, Guilan University of Medical Sciences, Rasht, Iran,
E-mail: yousha_pourahmadi@yahoo.com

Received Date: 09 May 2020

Accepted Date: 21 May 2020

Published Date: 23 May 2020

Citation:

Aghajanzadeh M, Fomani AA, Jafarnegad A, Tangestaninejad A, Pourahmadi Y. A Rare Case of Pulmonary Hydatid Cysts with Presentation of Pleural Effusion. *Clin Surg.* 2020; 5: 2830.

Copyright © 2020 Yousha Pourahmadi. This is an open access article distributed under the Creative Commons Attribution License, which permits unrestricted use, distribution, and reproduction in any medium, provided the original work is properly cited.

Introduction

Hydatid cysts are seen specially in Mediterranean country, the Middle East, and South Africa and its endemic in several countries like Turkey, Iran and South Africa [1,2]. Hydatid cysts can be found in any organ, but they are more common in the liver (65% to 75%) and lung [15%]. Pulmonary and liver hydatid cysts together occur in 4% to 25% of patients according to some reports [1,2], so if the diagnosis is pulmonary or hepatic cyst we should not rule out the possibility of cysts in other organs. Hydatid cysts can be ruptured in 5% of cases and symptoms are severe chest pain, anaphylaxis reaction, persistent cough, severe dyspnea, cyanosis, shock, and asphyxia with acute onset [3-5]. We may have peritonitis or pulmonary hydatidosis or a bronchial or pleural fistula base on the location of rupture into peritoneum or transdiaphragmatically into the pleural space or bronchial tree [3,6]. The most frequent complication of pulmonary hydatid disease is the rupture of the cyst into tracheo-bronchial tree [5-7]. If a cyst ruptures into the pleura or pulmonary parenchyma, it can be a severe and life-threatening, such as tension pneumothorax [2-5]. CXR and lung CT-scan along with the initial clinical presentation are useful for making the diagnosis [2,4,5]. Serological diagnosis of hydatid cysts may not be as useful as later tools because of low sensitivity and specificity [1-3]. The mainstay of treatment for pulmonary hydatid cysts is surgery. Pulmonary hydatid cysts's surgery includes the removal of the laminated membrane and care should be taken about intraoperative contamination and residual pulmonary cystic [2,3,7,8]. Here, we report an interesting case with rare presentation of pleural effusion and cystic lesions.

Case Presentation

A 20-year old young man with presentation of noticeable fever, left hemithorax pain, and intense dyspnea was admitted to local cardiac hospital. He lived in the village. Her physical examination revealed severe respiratory distress with a respiratory rate of 27 beats/ per min, tachycardia of 130/ per min, blood pressure of 100/60 mmHg, and decrease breath sounds at the left hemithorax. All lab data was normal. Other organ and limbs was normal. Chest radiograph taken on admission showed left side pleural effusion, mediastinal shift, and tracheal displacement. He was referred to our hospital from a local hospital. In emergency room intra venous fluid and expander volume therapy started. CT-scan of chest was taken and show collapse of left lung with loculated pleural effusion and a circular lesion in central portion of effusion (Figures 1-5), Tube thoracostomy was

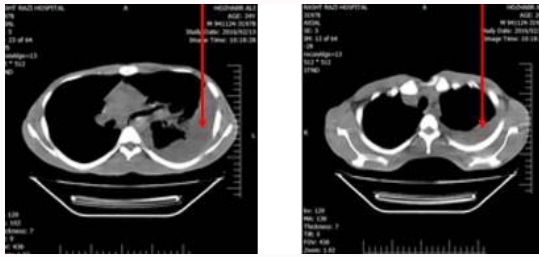


Figure 1 and 2: CT-scan of chest with red arrow show pleural effusion.

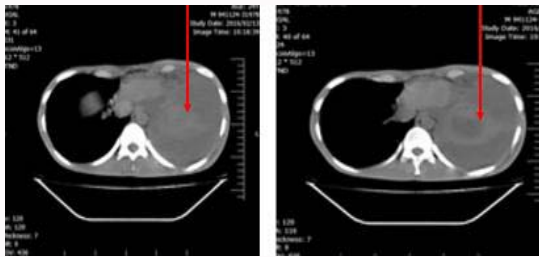


Figure 3 and 4: CT-scan of chest with red arrow show pleural effusion and central circular lesion.

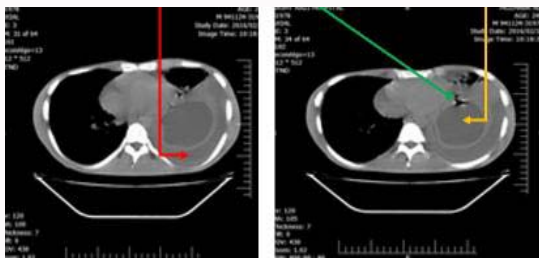


Figure 5 and 6: CT-scan of chest with red, yellow and green arrow show cyst and air bubble around the cyst.

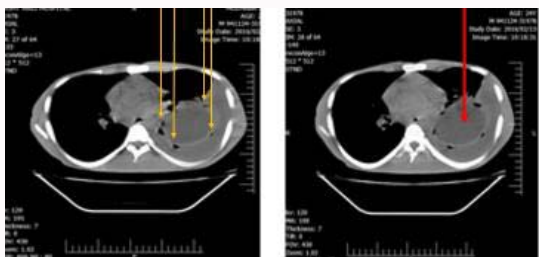


Figure 7 and 8: CT-scan of chest with red and yellow arrow show cyst and air bubble around the cyst.

placed, where there was a considerable air leak and yellow effusion. The same day, Left anterolateral thoracotomy was performed through the 5th intercostals space. During operation, displacing and compressing the left lower lobe was presented. During exploration, a laminated membrane of cyst was removed following by irrigation of pericystic cavity with normal saline (Figure 6). After removing all debris and using normal saline and positive intrapulmonary pressure, small bronchial orifices became visible. The orifices sutured interruptedly with 2-0 Vicryl. Then we preformed capitonage which means eliminating of the residual cavity using purse-string sutures that united the deepest of cavity to the surface. The fibrotic tissue of pricyst was removed Chest tube put in pleural space and chest wall was closed. Recovery from surgery in postoperative period

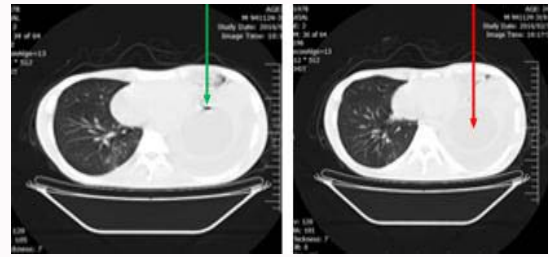


Figure 9 and 10: CT-scan of chest (paranchymal widow) with green and red arrow show air bubble around the cyst and cyst.

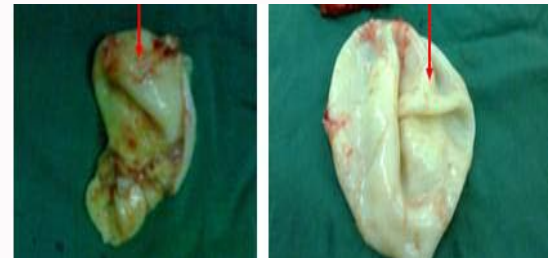


Figure 11 and 12: Shown laminated membran of pulmonary hydatid cyst in two view.

was so good that he was discharged on the sixth postoperative day. Histopathological confirmation of hydatid cyst was done later on. Albendazole (800 mg) daily was prescript for three of 28 day with 14 day interval. In six month follow-up there was no problem.

Discussion

Hydatid cysts disease is still an significant health issue in certain developing countries [1-4,9]. It can be found in any organs, but they are more common in the liver (65% to75%), lung [15%], and less frequent (about 10%) in other organs such as spleen, kidney, spine and muscle [2,4]. Pulmonary hydatid cysts are usually asymptomatic while symptoms may appear with increasing size over a period of time or in cases that cysts are in the central portion of lung or other complications [2,3,9,10]. A sudden rise in the intrapulmonary pressure, such as Trauma or even coughing, sneezing with the mechanisms of increasing intrapulmonary and intra-abdominal pressure is the main risk factor for rupturing of hydatid cysts [2,3,9,10]. However spontaneously rupture may occur without any risk factor [4,5]. Pleural effusion is a rare complication of pulmonary hydatid cyst after rupturing that can be detect in CT scan of lung [4-7]. The signs and symptoms of pleural effusion due to rupture of pulmonary hydatid cyst include severe dyspnea, tachycardia, chest pain fever and hypotension and rarely macular skin lesions were present on the chest, abdomen and both upper and lower extremities [4-7]. Hyporesonance on percussion of the affected hemithorax and lack of breath sounds in auscultation may indicate pleural effusion [4-6]. We reached to the diagnosis of ruptured pulmonary hydatid cyst with the help of physical examination especially auscultation and percussion of the chest, radiography's features, and histopathological confirmation. Serological diagnosis of hydatid cysts may not be as useful as later tools because of low sensitivity and specificity [1-3]. The mainstay of treatment for pulmonary hydatid cysts is surgery [3,5,8]. Pulmonary hydatid cyst's surgery includes the removal of the laminated membrane and care should be taken about intraoperative contamination and residual pulmonary cystic [2,3,7,8]. In order to have best results in surgery several techniques recommended

such as enucleation, pericystectomy, and simple cystotomy with or without capitonnage of the pericystic cavity [3,8,10]. In cases with pleural effusion due to rupture of cysts, we usually remove laminated membrane, perform pericystectomy, elimination the residual cavity by purse-string sutures from deepest of cavity to the surface (capitonnage) and finally remove pleural membrane (decortication) [1,3]. Any destroyed pulmonary parenchyma around the hydatid cyst should be resected with wedge pulmonary resection [2,3,8]. In our case we preformed thoracotomy and evacuation of effusion and laminated membrane with irrigation of pleural space without any morbidity and mortality.

Conclusion

Ruptured pulmonary hydatid cyst is an important differential diagnosis of primary pleural effusion as a complication of hydatid cyst especially in endemic area and surgical operation should be performed as soon as possible. Medical therapy with albendazole for distinct period of time after surgery is imperative to prevent recurrence.

References

1. Aghajanzadeh M, Safarpour F, Amani H, Alavi A. One-stage procedure for lung and liver hydatid cysts. *Asian Cardiovasc Thorac Ann.* 2008;16:392-5.
2. Aghajanzadeh M, Kiaabadi AR, Mohtasham B, Saravi MK, Mosafai O, Ghotbi F. One-staged anterolateral thoracotomy for bilateral lung hydatid cysts. *Ann Trop Med Public Health.* 2017;10:1601-6.
3. Aghajanzadeh M, Asgary MR, Alavi Foumani A, Alavi SE, Rimaz S, Banihashemi Z. Surgical management of pleural complications of lung and liver hydatid cysts in 34 patients. *Int J Life Sci.* 2014;8:15-19.
4. Ekim H, Ekim M. Echinococcal tension pneumothorax in a pregnant woman. *Pak J Med Sci.* 2009;25:159-61.
5. Puri D, Mandal AK, Kaur HP, Mahant TS. Ruptured hydatid cyst with an unusual presentation. *Case Rep Surg.* 2011;2011:730604.
6. Chacko J, Raot S, Basawaraj K, Chatterjee S. Ruptured hydatid cyst masquerading as tension pneumothorax. *Anaesth Intensive Care.* 2009;37:840-2.
7. Yekeler E, Celik O, Becerik C. A giant ruptured hydatid cyst causing tension pneumothorax and hemothorax in a patient with blunt thoracic trauma: A rare case encountered in the emergency clinic. *J Emerg Med.* 2012;43:111-3.
8. Cobanoglu U, Sayir F, Sehitoğlu A, Bilici S, Melek M. Therapeutic strategies for complications secondary to hydatid cyst rupture. *Int J Clin Exp Med.* 2011;4(3):220-6.
9. Lal C, Huggins JT, Sahn SA. Parasitic diseases of the pleura. *Am J Med Sci.* 2013;345:385-9.
10. Kürkçüoğlu IC, Eroğlu A, Karaoğlanoğlu N, Polat P. Tension pneumothorax associated with hydatid cyst rupture. *J Thorac Imaging.* 2002;17(1):78-80.