



A Practical Tip to Optimize the c-TBNA Yield

Maria Majori^{1*}, Elisabetta Teopomp², Enrico Martinelli² and Francesco Andran²

¹Pulmonology and Thoracic Endoscopy Unit, University Hospital of Parma, Parma, Italy

²Respiratory Disease and Lung Function Unit, University of Parma, Italy

Clinical Image

The introduction of the Endobronchial Ultrasound (EBUS) in the clinical practice should not reduce the importance of Conventional Transbronchial Needle Aspiration (c-TBNA) where recommended, as a first line diagnostic method in order to have a more cost-effective strategy [1]. EBUS-TBNA, in fact, is much more expensive than TBNA from different point of view (e.g. high cost of the EBUS instrument and aspiration needles, need for additional skills and deep sedation of the patient) and in case of large mediastinal lymphadenopathies in selected stations according to Wang's map [2] c-TBNA should be performed before EBUS-TBNA. In our clinical practice, in *pre-EBUS era*, we optimized the yield of c-TBNA through a practical tip developed in order to ameliorate the spatial orientation of the interventional pulmonologist in the tracheobronchial tree and overcome the “blindness” of TBNA that is the main limit of its widely use. Our method entails a mental 3-dimensional reconstruction of radiologic images through an integration of the radiologic imaging of the mediastinum with anatomic landmarks [3]. The carina position on chest Computed Tomography (CT) represents our landmark; we measure the distance between carina and the target Lymph Node (LN) multiplying the number of images between one another by the distance between two images; the CT image of the target LN (Figure 1A) is then turned around to match the orientation of the endoscopic view (Figure 1B). Next step is to print this image and to highlight the interested area and finally put in front of a light source, so it can be clearly seen inside the endoscopic room (Figure 1C). This practical approach allowed us to reach a diagnostic yield of 62% to 69% in LNs ≥ 15 mm in stations 4R and 7 from patients with lung cancer, sarcoidosis and other [4]. In addition, within a total of 52 patients with diagnosis of adenocarcinoma identified by c-TBNA, it was also possible to perform EGFR molecular analysis in 52 patients (100%) and ALK molecular analysis in 50 patients (91%). In era of targeted agents, such as Epidermal Growth Factor Receptor tyrosine kinase inhibitors (EGFR) or Anaplastic Lymphoma Kinase (ALK) inhibitors and immune checkpoint blockades whose target is represented by inhibitory immune molecules as Programmed Death-Ligand 1 (PD-L1) and its receptor (PD-1), or Cytotoxic T-Lymphocyte-Associated Antigen 4 (CTLA-4) [5], the biological characterization of non-small cell lung cancer cannot avoid EBUS-TBNA. However, in selected clinical setting with a high probability of success from the conventional procedure an initial approach with c-TBNA could be considered [6]. Stage I sarcoidosis is the most common diagnosis made by this stepwise approach based on LN size, station and presumed diagnosis, especially in LNs of size ≥ 20 mm at stations 7, 4R and 11R [7]. So, as example of our *modus operandi*, we report a case of stage I sarcoidosis in a 36-year-old woman who presented with a asthenia, significant weight loss and erythema nodosum (Figure 1). Chest CT showed swelling of the

OPEN ACCESS

*Correspondence:

Maria Majori, Pulmonology and Thoracic Endoscopy Unit, University Hospital of Parma, Parma, Italy,
E-mail: mmajori@ao.pr.it

Received Date: 15 Nov 2019

Accepted Date: 20 Nov 2019

Published Date: 27 Nov 2019

Citation:

Majori M, Teopomp E, Martinelli E, Andran F. A Practical Tip to Optimize the c-TBNA Yield. *Clin Surg.* 2019; 4: 2671.

Copyright © 2019 Maria Majori. This is an open access article distributed under the Creative Commons Attribution License, which permits unrestricted use, distribution, and reproduction in any medium, provided the original work is properly cited.

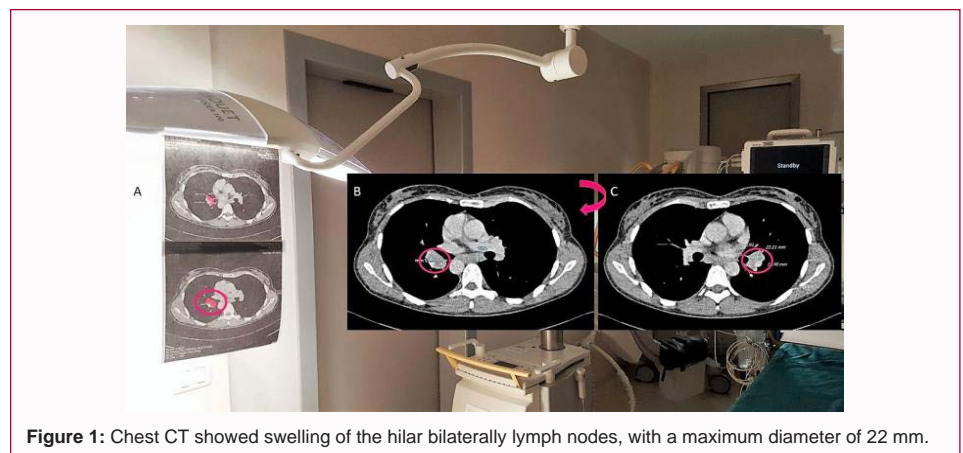


Figure 1: Chest CT showed swelling of the hilar bilaterally lymph nodes, with a maximum diameter of 22 mm.

hilar bilaterally lymph nodes, with a maximum diameter of 22 mm (Figure 1) with significant uptake at Fluorodeoxyglucose Positron-Emission Tomography/CT (FDG PET). Diagnosis of sarcoidosis was made by c-TBNA also thanks to ours practical tip. We wish to report our experience in spite of growing trend to abandon c-TBNA probably due to a lack of confidence with this procedure. There is no doubt that EBUS-TBNA has an incomparable role in mediastinal staging or re-staging after induction therapy and for sampling of small lesions (<15 mm) far from the carina; however, especially in the case of presumed sarcoidosis or small cell lung cancer, an initial approach with TBNA should be done so also in center where EBUS is available.

References

1. Fiorelli A, Santoriello C, Di Natale D, Cascone R, Musella V, Mastromarino R, et al. In the era of ultrasound technology, could conventional transbronchial needle aspiration still play a role in lung cancer mediastinal staging? *J Thorac Dis.* 2017;9(5):S386-S94.
2. Wang KP. Staging of bronchogenic carcinoma by bronchoscopy. *Chest.* 1994;106(2):588-93.
3. Ceron L. "Tips and Pitfalls" in Transbronchial Needle Aspiration. *J Bronchol.* 2005;12:249-53.
4. Majori M, Anghinolfi M, Scarascia A, Nizzoli R, Casalini AG. Conventional transbronchial needle aspiration with 23 gauge needle: a preliminary study. *J Thorac Dis.* 2015;7:758-63.
5. Sui H, Ma N, Wang Y, Li H, Liu X, Su Y, et al. Anti-PD-1/PD-L1 Therapy for Non-Small-Cell Lung Cancer: Toward Personalized Medicine and Combination Strategies. *J Immunol Res.* 2018;2018:6984948.
6. Bonifazi M, Tramacere I, Zuccatosta L, Mei F, Sediari M, Paonessa MC, et al. Conventional versus ultrasound-guided transbronchial needle aspiration for the diagnosis of hilar/mediastinal lymph adenopathies: a randomized controlled trial. *Respiration.* 2017;94:216-23.
7. Liran L, Rottem K, Gregorio FZ, Avi A, Neville B. A novel, stepwise approach combining conventional and endobronchial ultrasound needle aspiration for mediastinal lymph node sampling. *Endosc Ultrasound.* 2019;8(1):31-35.