Clinics in Surgery

Case Report
Published: 10 May, 2019

A Novel Management of Infected Metacarpophalangeal Joint Silicone Arthroplasty with Antibiotic-Impregnated Spacer

Meng Guo[1], Kyle Lineberry[1] and Hani Matloub[1,2]*

[1]*Department of Plastic Surgery, The Medical College of Wisconsin, USA*

[2]*Clement J. Zablocki VA Medical Center, USA*

Abstract

Osteoarthritis of the Metacarpophalangeal (MCP) joint is a relatively rare condition that can be treated surgically with arthroplasties using silicone implants once conservative management has failed. Infection rates are low, but its consequences can be devastating when it does occur. We present a novel management of an infected MCP joint silicone arthroplasty with the use of a custom-made antibiotic-impregnated spacer in conjunction with systemic antimicrobial therapy. The patient was successfully treated using a two-stage exchange approach and subsequently gained functional range of motion in the affected joint.

Keywords: Osteoarthritis; Metacarpophalangeal joint; Silicone arthroplasty; Antibiotic spacer

Introduction

Osteoarthritis is quite common however osteoarthritis of the Metacarpophalangeal (MCP) joint is relatively rare. The index and middle fingers are the most commonly affected digits [1]. Symptoms of MCP osteoarthritis include pain and decreased range of motion. Initial treatment includes activity modifications, Non-steroidal Anti-Inflammatory Drugs (NSAIDs), and intra-articular corticosteroid injections. If conservative management fails to provide adequate and sustained symptomatic relief, surgical intervention such as arthrodesis and arthroplasty are options. Arthroplasty has been shown to be an effective treatment at the MCP joint as it maintains pre-operative range of motion and improved function when compared to joint fusion [2]. The most common type of arthroplasty used at the MCP joint is the silicone implant. It has proven to provide good hand function with high patient satisfaction and pain relief [3].

Placement of prosthetic implants in the MCP joint is not without complications. Infection rates of 3.5% have been reported with the most commonly isolated organisms being *Staphylococcus aureus* and other *Staphylococcus* spp. [4]. Prosthetic joint infections are difficult to treat and often require implant removal. Many of the causative pathogens have a propensity to form biofilms that are hard to eradicate. Overall, the general principles of treatment include obtaining accurate microbiological diagnoses to allow for targeted medical therapy in conjunction with aggressive surgical debridement of the infected tissue and removal of the affected prosthesis while maintaining sufficient soft tissue coverage to allow for wound healing [5].

The two-stage arthroplasty exchange has long been used in the treatment of shoulder, hip, and knee arthroplasty infections with a reported success rate of greater than 85% [5]. This approach involves obtaining intra-operative cultures prior to thorough debridement and hardware removal with placement of an antibiotic spacer (Stage 1), followed by a 4 to 6 weeks course of targeted antibiotic therapy and a period of close monitoring off treatment. Once infection has been eradicated, the patient is taken to the operating room once more for spacer removal and placement of a new prosthesis (Stage 2). Though this two-stage exchange has been used in the treatment of hardware infections in large joints, there has been a paucity of studies describing its efficacy in the treatment of small joint hardware infections. Thus, we present a case of an infected MCP joint silicone arthroplasty successfully treated with the two-stage exchange approach using a custom-made antibiotic spacer.

Case Presentation

A 60-year-old man with osteoarthritis of the radial three MCP joints bilaterally, for which he had

OPEN ACCESS

Correspondence:
Meng Guo, Department of Plastic Surgery, The Medical College of Wisconsin, USA, Tel: 414-795-7870; E-mail: mguo@mcw.edu

Received Date: *28 Mar 2019*
Accepted Date*: 02 May 2019*
Published Date*: 10 May 2019*

Citation:
Guo M, Lineberry K, Matloub H. A Novel Management of Infected Metacarpophalangeal Joint Silicone Arthroplasty with Antibiotic-Impregnated Spacer. Clin Surg. 2019; 4: 2424.

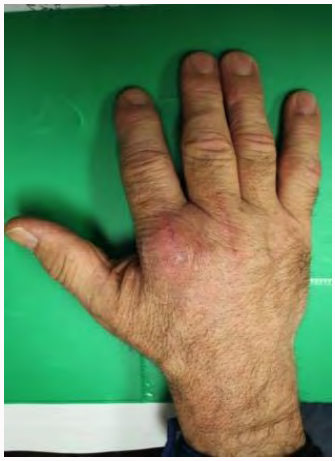

Figure 1: Right index finger MCP joint infection six weeks after silicone arthroplasty.

Figure 2: Custom-made right index finger MCP joint antibiotic-impregnated spacer.

previously undergone MCP joint arthrodesis of the bilateral thumbs, now presented with right index and middle finger MCP joint pain unrelieved with activity modifications, NSAIDs, and intra-articular corticosteroid injections. The patient was otherwise healthy, but he was an active smoker.

Physical exam revealed tenderness to palpation over the MCP joints of the right index and middle fingers with radiographic imaging that demonstrated joint space narrowing with associated erosions and osteophytes at these sites.

In October 2017, the patient underwent right index and middle finger MCP joint arthroplasties with Swanson silicone implants via the standard technique. He received 2 grams of cefazolin pre-operatively. After bathing the implants and thoroughly irrigating the MCP joint recipient sites with bacitracin solution, the implants were placed and again irrigated well prior to closure. He was discharged home on the same post-operative day.

Six weeks after the procedure, the patient developed pain, erythema, edema, and serous drainage from his right index finger (Figure 1). A culture of the drainage was obtained and the patient was empirically started on oral sulfamethoxazole/trimethoprim. However the next day the patient presented with purulent drainage from the wound and he was admitted to the hospital and started on intravenous ampicillin/sulbactam. Cultures of the wound grew *Staphylococcus aureus* and coagulase negative *Staphylococcus*. He was taken to the operating room and underwent washout of the right index finger MCP joint with removal of the hardware. After silicone

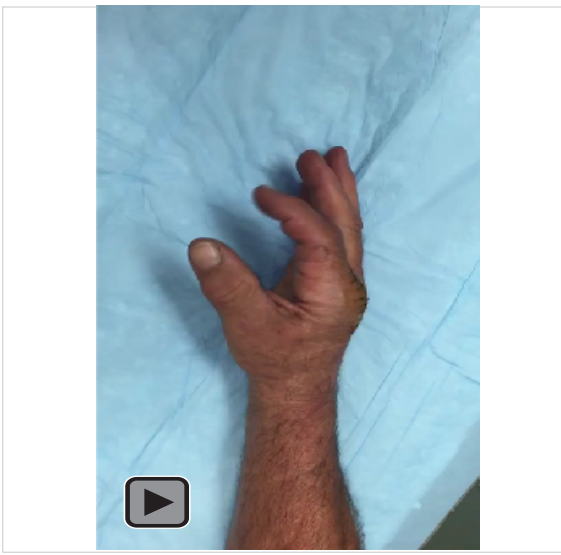

Video 1: Demonstration of functional range of motion of the right index finger MCP joint one month after antibiotic spacer removal and revision silicone arthroplasty.

implant removal and washout of the wound an antibiotic spacer was fashioned out of methyl methacrylate beads infused with tobramycin and vancomycin solution. The implant was designed as an ellipsoid tubular structure measuring 2 cm by 0.5 cm at the widest width and tapered at both ends (Figure 2). Once the spacer hardened, it was placed in the MCP joint of the right index finger under traction and the wound was closed. The patient was started on intravenous nafcillin and oral rifampin for a total of six weeks followed by oral cephalexin for six additional months as preventative therapy given that he had hardware in place. He was allowed to resume post-operative hand therapy.

Once the patient had completed the full course of the antibiotic regimen and monitored for three additional months off antibiotics without return of infectious symptoms, he was again taken to the operating room, one year after his initial procedure, and underwent removal of the antibiotic spacer and revision right index finger MCP joint arthroplasty with placement of a Swanson silicone implant. This post-operative course was notable for serosanguinous drainage from his surgical wound on post-operative day seven, for which he was treated empirically with a seven-day course of oral cephalexin. Cultures obtained at this time again grew coagulase negative *Staphylococcus*. The drainage resolved without further intervention and he was followed closely in clinic. It is now four months following the revision arthroplasty and the patient is recovering well and working with hand therapy. He has gained functional range of motion of the right index finger MCP joint (Video 1).

Discussion

Osteoarthritis of the MCP joints can significantly affect hand function. If conservative management fails to provide prolonged symptomatic relief, surgical interventions should be considered. Silicone arthroplasty has been proven to provide excellent pain relief and functional range of motion in these patients, though post-operative infection may require removal of the implant.

Two-stage arthroplasty exchange for the treatment of hardware infections have been used as the gold standard approach in larger

joints such as the hips and knees with reported success rates of greater than 85% [5]. However, there exists little literature on the efficacy of this approach in small joint arthroplasty infections such as reported in this case. Antibiotic spacers are available as pre-fabricated implants or can be prepared in the operating room by the surgeon in real time. The latter allows the surgeon to not only tailor the antibiotics used, but also to customize the shape of the spacer needed. Additionally, surgeon-prepared spacers allow for the use of multiple antibiotics to better target the antimicrobial profile of each distinct prosthetic joint infection. The combination of multiple antibiotics into bone cement has been shown to provide a synergistic effect. In an *in vitro* study performed by Penner et al. [6], the combination of tobramycin and vancomycin enhanced the elution of both antibiotics by 68% and 103%, respectively.

In this case report, the patient's pre-operative cultures grew *Staphylococcus aureus* and coagulase negative *Staphylococcus*, which are among the most common pathogens isolated in prosthetic joint infections [4]. We opted to use a combination of tobramycin and vancomycin to ensure targeted broad-spectrum coverage of both Gram positive and Gram negative organisms. The antibiotic infused implant was then shaped specifically to fit the patient's right index finger MCP joint defect and he was allowed to continue post-operative hand therapy with the spacer in place. The patient has recovered well from the procedure and has maintained functional range of motion despite the complication.

Our case demonstrates in the small joints of the hand, a well-fitted antibiotic spacer has the potential to allow the patient to continue therapy prior to re-implantation of a permanent prosthetic joint and avoid fusion of the joint. This case report thus highlights the utility of the two-stage arthroplasty exchange using a custom-made antibiotic spacer in the treatment of small joint hardware infections.

References

1. Morrell NT, Weiss AC. Silicone Metacarpophalangeal Arthroplasty for Osteoarthritis: Long-Term Results. J Hand Surg Am. 2018;43(3):229-33.
2. Rizzo M. Metacarpophalangeal joint arthritis. J Hand Surg Am. 2011;36(2):345-53.
3. Neral MK, Pittner DE, Spiess AM, Imbriglia JE. Silicone Arthroplasty for Non rheumatic metacarpophalangeal Joint arthritis. J Hand Surg Am. 2013;38(12):2412-418.
4. Gellman H, Stetson W, Brumfield RH Jr, Costigan W, Kushner SH. Silastic metacarpophalangeal joint arthroplasty in patients with rheumatoid arthritis. Clin Orthop Relat Res. 1997;342:16-21.
5. Tande AJ, Gomez-Urena EO, Berbari EF, Osmon DR. Management of Prosthetic Joint Infection. Infect Dis Clin North Am. 2017;31(2):237-52.
6. Penner MJ, Masri BA, Duncan CP. Elution characteristics of vancomycin and tobramycin combined in acrylic bone-cement. J Arthroplasty. 1996;11(8):939-44.