Clinics in Surgery

Case Report
Published: 20 Apr, 2017

A Minimally Invasive Technique Using Tubular Retractors for Percutaneous Transpedicular Fixation of Traumatic Spondylolisthesis of Axis: A Case Report and Technical Note

Shanu Gambhir[1], Idrees Sher[2]*, Yagnesh Vellore[3] and Mark Winder[4]

[1]*Department of Neurosurgery, St. Vincent's Hospital, Australia*

[2]*Department of Neurosurgery, Monash Medical Centre, Australia*

[3]*Department of Neurosurgery, Austin Hospital, Australia*

[4]*Department of Neurosurgery, St. Vincent's Hospital, Australia*

Abstract

Hangman's type fractures are notoriously difficult to manage. Conservative management often fails in the more severe fracture types resulting in a significant source of burden particularly in the setting of unstable fractures. Numerous management strategies have been described including conservative non-surgical options such as an external cervical orthosis or halo thoracic jacket brace to operative management strategies that can be invasive, carry risk of neurovascular injury and morbidity and be motion restricting.

We describe a minimally invasive, muscle sparing, motion preserving C2 transpedicular (pars interarticularis) screw construct technique without the use of k-wires in a 72 year old man with a Levine and Edward's type II Hangman fracture that failed conservative management. To the best of our knowledge, this is the first case report describing this technique.

Keywords: Cervical spine; Hangman's fracture; Transpedicular screw; Minimally invasive surgery; Tubular retractor

OPEN ACCESS

Correspondence:
Idrees Sher, Department of Neurosurgery, Monash Medical Centre, Clayton, Victoria, Australia. Tel: +61448632798;
E-mail: reece.sher@me.com

Received Date: *01 Dec 2016*
Accepted Date*: 10 Apr 2017*
Published Date*: 20 Apr 2017*

Citation:
Gambhir S, Sher I, Vellore Y, Winder M. A Minimally Invasive Technique Using Tubular Retractors for Percutaneous Transpedicular Fixation of Traumatic Spondylolisthesis of Axis: A Case Report and Technical Note. Clin Surg. 2017; 2: 1409.

Introduction

Traumatic spondylolisthesis of the axis (TSA) is the second most common fracture type of the second cervical vertebra (C2), accounting for 4%–20% of all cervical spine injuries [1,2]. It involves a bilateral fracture of the C2 pars interarticularis with variable displacement of C2 on C3. In 1965, Schneider "et al." [3] coined the term "Hangman's" fracture to describe this injury based on its superficial similarity to the injury seen after judicial hanging caused by severe hyperextension and distraction. In 1981, Effendi "et al." [4] defined 3 types of fractures of the ring of the axis based on the mechanism of injury. However, in 1985, Levine and Edwards (L-E) [5] modified the Effendi classification by adding flexion-distraction as a mechanism of injury (type IIA), representing a total of 4 injury types:

a. Type I fracture as having < 3 mm of displacement with no angulation

b. Type II, > 3 mm of displacement with angulation (< 10°)

c. Type IIa, minimal displacement but C2–3disc disruption and significant angulation (>10°)

d. Type III, a Type II injury with associated bilateral C2–3 facet dislocation [5].

These classification systems enable an estimation of fracture stability and help guide management [6]. Stable fractures (L-E Types I and II) are generally treated with an external cervical orthosis such as a rigid cervical collar or halo immobilization [7]. Surgical management is indicated for most unstable fractures (including some L-E Type II, and most Type IIa and III fractures) [8],when external brace immobilisation fails or when prolonged immobilisation is considered untenable [8].

Various anterior and posterior surgical options have been described in the literature. Posterior approaches may involve a C1–2 or C1–3 posterior cervical fusion with occasional occiput

Figure 1: Sagittal and axial CT images of the bilateral C2 pars interarticularis fractures aka 'Hangman's fracture'.

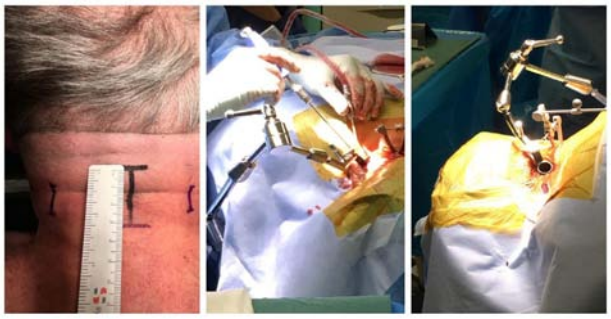

Figure 2: Bilateral 1.5cm and midline skin incisions marked (left image). The images to the right and middle demonstrate the intraoperative use of MIS tubular retractor system and stereotactic guidance.

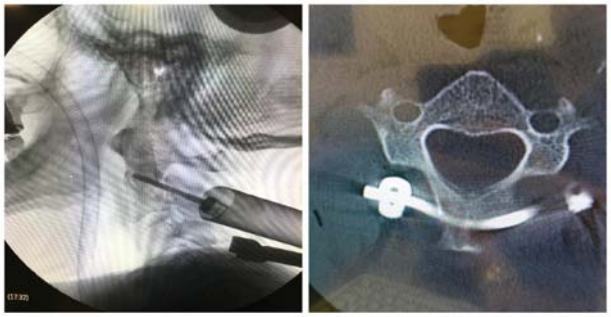

Figure 3: Left image demonstrates intraoperative image intensifier visualisation of pars interarticularis aka 'pedicle' screw insertion. Right image demonstrates post-op CT of rod-screw construct *in situ*.

incorporation, whereas anterior approaches usually includes C2–3 anterior cervical discectomy and fusion [8-12]. Direct pars fixation has been described as an alternative for Hangman fractures with limited disk and ligamentous injury but may be the most technically challenging procedure [13,14].

We describe a new minimally invasive surgical technique (MIS) for insertion of C2 transpedicular (pars interarticularis) screws reinforced with a posterior interconnecting rod, without the use of K-wires. We use a tubular retractor system and stereotactic navigation to aid in this muscle sparing, motion preserving technique. To the best of our knowledge, there has been no prior report of this technique in the literature.

Case Presentation

A 72-year-old male was brought in by ambulance with neck pain following a fall from an escalator. He suffered abrasions and scalp lacerations but no other relevant injuries. His background was significant for atrial fibrillation requiring warfarin. On Examination, he was GCS 15 and was neurologically intact. CT scan of brain was unremarkable. CT scan of the cervical spine demonstrated a Hangman's fracture traversing the left vertebral foramen of C2 (Figure 1) consistent with an L-E type II fracture. CT angiogram of vertebral arteries was unremarkable. The patient was initially managed conservatively with a rigid cervical collar for 3 months. However, he complained of persistent neck pain and follow up CT of cervical spine showed fracture non-union. In light of his ongoing symptoms and fracture non-union, the decision was made for surgical intervention in the form of posterior cervical MIS C2 transpedicular screw and rod construct fixation using tubular retractors and stereotactic navigation.

Surgical Technique

The patient underwent fibre optic intubation under spinal precautions. Mayfield head clamp was applied and the patient was carefully positioned prone on a Wilson frame. Lateral intraoperative image intensifier (II) imaging was utilised to ensure adequate reduction of the C2 fracture. The pre-operative stereotactic CT cervical spine was registered and three stereotactic skin incisions were marked: a 3cmmidline and two paramedian 1.5 cm incisions. Brainlab stereotactic navigation system allowed for accurate trajectory mapping for both C2 pedicle screws (Figure 2). A midline cervical incision was performed exposing bilateral C2 and C3 lamina, allowing local registration and subsequently enabling for posterior rod placement between the C2 pedicle screws. Bilateral 1.5cm skin incisions were made and the Medtronic Metrx II 18 mm tubular retractor system was docked onto the C2 laminae. This allowed for the medial trajectory of the C2 pedicle screws (Figure 3). Under navigation a powered drill was used to target the pedicle allowing for 38 mm (length) x 4mm (diameter) screws to be positioned traversing the fracture. Stereotactic imaging accuracy was confirmed with II. A partial C2 spinous process osteotomy was performed to allow for a 40 mm fashioned rod to be placed, interconnection both C2 pedicle screws. Layered closure was undertaken in a routine fashion. Blood loss was approximately 50 ml.

Follow-up

There were no intraoperative surgical complications and the patient progressed well postoperatively without neurologic deficit. Post-operative cervical spine CT demonstrated good position of the C2 transpedicular screw construct (Figure 4). The patient was mobilised from day 0 and was discharged two days later. A rigid cervical collar was applied for a further 6 weeks postoperatively. Follow up CT at 3 months demonstrated fracture union and satisfactory construct position. Clinically, the patient was asymptomatic.

Discussion

The primary management of Hangman type fractures is typically non-surgical. However, management approaches remain controversial with 'the most effective' treatment option being a hot topic of debate [8]. Li "et al." published a meta-analysis (32 papers, 357 patients) of non-operative management of hangman fractures according to the L-E classification and reported fracture healing rates of 100%, 60%, 42%, and 38% for patients with L-E Type I, II, IIa, and III fractures, respectively [7].

Surgical management is indicated for various reasons including

failure of conservative management, non-compliance, fracture severity and instability [7]. Various surgical options have been described in the literature including posterior and anterior stabilization. Posterior stabilization includes C1–2 and C1–3 posterior cervical fusion with occasional occipital extension whilst anterior surgery usually includes C2–3 anterior cervical discectomy and fusion [8-12]. In 2009, Dalbayrak "et al." [13] described 4 patients with L-E type II Hangman fractures treated with C2 pars fixation. All 4 patients progressed to successful fracture union. Boullosa "et al." [14] reported 10 Hangman fracture patients successfully treated with C2 transpedicular fixation after failure of external immobilization and where a halo device was contraindicated. They also described a 100% fracture union rate.

Bilateral transpedicular screw fixation is a motion-preserving technique, however, it requires a large occipito cervical skin incision to obtain adequate medial screw trajectory for the C2 pedicle, results in disruption of posterior cervical musculature and post-operative pain and carries the potential for neuro-vascular injury [15]. Recently, percutaneous minimally invasive surgical techniques (MIS) have gained popularity amongst spine surgeons and offer several advantages, including shorter lengths of hospital stay, decreased pain, and shorter recovery times, less blood loss, lower infection rates, and preservation of surrounding anatomical structures [16].

Wu "et al." [17] were the first to report the use of percutaneous transpedicular screw fixation for Hangman's fractures. However, they used preoperative imaging to ascertain entry points and angles rather than a dedicated computerized neuro-navigation system. In 2015, Buchhloz "et al." [18] described a series of 5 patients using a minimally invasive technique for placement of percutaneous C2 pedicle screws for Hangman's fracture incorporating intraoperative 3D fluoroscopy and neuro-navigation. They inserted C2 pedicle screws via two paramedian skin incisions using k-wires, however, the screws were not connected by rod so the posterior ring was not reinforced.

We describe a new MIS technique for the insertion of C2 transpedicular (pars interarticularis) screws using a tubular retractor system and stereotactic navigation without using K-wires. This technique enables the incorporation of a posterior rod reinforcing the posterior ring, potentially serving to increase biomechanical stability whilst adopting a muscle sparing approach.

Conclusion

To the best of our knowledge, this is the first report to describe the use of tubular retractor system for placement of stereotactic MIS C2 transpedicular screws and incorporating a posterior rod for the surgical treatment of a Hangman's fracture. It represents a safe and intuitive option for the surgical management of unstable C2 fractures adding to the expanding literature of evolving minimally invasive spinal techniques.

References

1. Roda JM, Castro A, Blázquez MG. Hangman's fracture with complete dislocation of C-2 on C-3. Case report. J Neurosurg. 1984;60(3):633-5.
2. Hadley MN, Browner C, Sonntag VK. Axis fractures: a comprehensive review of management and treatment in 107 cases. Neurosurgery. 1985;17(2):281-90.
3. Schneider RC, Livingston KE, Cave AJ, hamilton G. "Hangman's Fracture" of the cervical spine. J Neurosurg. 1965;22:141-54.
4. Effendi B, Roy D, Cornish B, Dussault RG, Laurin CA. Fractures of the ring of the axis. A classification based on the analysis of 131 cases. J Bone Joint Surg Br. 1981;63-B(3):319-27.
5. Levine AM, Edwards CC. The management of traumatic spondylolisthesis of the axis. J Bone Joint Surg Am. 1985;67(2):217-26.
6. Moon MS, Moon JL, Moon YW, Sun DH, Choi WT. Traumatic spondylolisthesis of the axis: 42 cases. Bull Hosp Jt Dis. 2001;60(2):61-6.
7. Li XF, Dai LY, Lu H, Chen XD. A systematic review of the management of hangman's fractures. Eur Spine J. 2006;15(3):257-69.
8. Ryken TC, Hadley MN, Aarabi B, Dhall SS, Gelb DE, Hurlbert RJ, et al. Management of isolated fractures of the axis in adults. Neurosurgery. 2013;72 Suppl 2:132-50.
9. Apfelbaum RI, Lonser RR, Veres R, Casey A. Direct anterior screw fixation for recent and remote odontoid fractures. J Neurosurg. 2000;93(2 Suppl):227-36.
10. HakaĹ,o J, Pezowicz C, Wroński J, Bedziński R, Kasprowicz M. The process of subsidence after cervical stabilizations by cage alone, cage with plate and plate-cage. A biomechanical comparative study. Neurol Neurochir Pol. 2007;41(5):411-6.
11. Müller EJ, Wick M, Muhr G. Traumatic spondylolisthesis of the axis: treatment rationale based on the stability of the different fracture types. Eur Spine J. 2000;9(2):123-8.
12. Ying Z, Wen Y, Xinwei W, Yong T, Hongyu L, Zhu H, et al. Anterior cervical discectomy and fusion for unstable traumatic spondylolisthesis of the axis. Spine (Phila Pa 1976). 2008;33(3):255-8.
13. Dalbayrak S, Yilmaz M, Firidin M, Naderi S. Traumatic spondylolisthesis of the axis treated with direct C2 pars screw. Turk Neurosurg. 2009;19(2):163-7.
14. Boullosa J, Colli BO, Carlotti CG Jr, Tanaka K, dos Santos MB. Surgical management of axis "traumatic spondylolisthesis (Hangman"s frature). Arquivos de Neuro-Psiquiatria. 2004;62(3b):821-26.
15. White AA 3rd, Panjabi MM. The basic kinematics of the human spine. A review of past and current knowledge. Spine (Phila Pa 1976). 1978;3(1):12-20.
16. Starkweather AR, Witek-Janusek L, Nockels RP, Peterson J, Mathews HL. The multiple benefits of minimally invasive spinal surgery: results comparing transforaminal lumbar interbody fusion and posterior lumbar fusion. J Neurosci Nurs. 2008;40(1):32-9.
17. Wu YS, Lin Y, Zhang XL, Tian NF, Sun LJ, Xu HZ, et al. Management of hangman's fracture with percutaneous transpedicular screw fixation. Eur Spine J. 2013;22(1):79-86.
18. Buchholz AL, Morgan SL, Robinson LC, Frankel BM. Minimally invasive percutaneous screw fixation of traumatic spondylolisthesis of the axis. Journal of Neurosurgery: Spine. 2015;22(5):459-65.